

A Practice Guideline on Wilson Disease

Eve A. Roberts¹ and Michael L. Schilsky²

Preamble

This guideline is intended for use by physicians. It describes preferable up-to-date approaches to the diagnosis and treatment of patients with Wilson disease. As their purpose is to direct patient care, these guidelines should not be considered inflexible mandates. They have been developed in a manner consistent with the American Association for the Study of Liver Diseases Policy Statement on Development and Use of Practice Guidelines.

These guidelines provide data-supported approaches to the diagnosis and management of patients with Wilson disease. They are based on, first, broad-based review of the published literature in pediatrics and medicine including Medline searches on hepatolenticular degeneration and related subjects; and second, 40 accumulated years of personal experience of the authors. In order to standardize recommendations as much as possible, each has been characterized with Roman numerals I through IV to indicate the quality of evidence on which the recommendation is based (Table 1).¹ A significant problem with the literature on Wilson disease is that patients are sufficiently rare to preclude large cohort studies or randomized controlled trials; moreover, most treatment modalities were developed at a time when conventions for drug assessment were less stringent than currently.

Introduction

Wilson disease (WD; hepatolenticular degeneration) was first described in 1912 by Kinnear Wilson as “progressive lenticular degeneration,” a familial, lethal neurologic disease accompanied by chronic liver disease leading to cirrhosis.² The association of corneal copper deposits with this disorder was later

made by Kayser and Fleischer.³ Over the next several decades the role of copper in the pathogenesis of WD was established, and the pattern of inheritance was determined to be autosomal recessive.⁴ In 1993 the gene that is abnormal in WD was identified.⁵⁻⁸ The gene, *ATP7B*, sometimes also referred to as “*WND*,” encodes a metal-transporting P-type ATPase, which is expressed mainly in hepatocytes and functions in the transmembrane transport of copper. Absent or reduced function of *ATP7B* protein leads to decreased hepatocellular excretion of copper into bile. This results in hepatic copper accumulation and injury. Eventually copper is released into the bloodstream and deposited in various other organs, notably the brain, kidneys, and cornea. Failure to incorporate copper into ceruloplasmin is an additional consequence of the loss of functional *ATP7B* protein. The hepatic production and secretion of the ceruloplasmin protein without copper, apoceruloplasmin, results in the decreased blood level of ceruloplasmin found in most patients with WD due to the reduced half-life of the apoprotein.⁹

WD occurs worldwide with an average prevalence of ~30 affected individuals per million population.¹⁰ It can present clinically as liver disease, as a progressive neurologic disorder (hepatic dysfunction being less apparent or occasionally absent), or as psychiatric illness. WD presents with liver disease more often in children and younger adult patients than in older adults. Symptoms at any age are frequently nonspecific.

WD was uniformly fatal until treatments were developed a half-century ago. WD was one of the first liver diseases for which effective pharmacologic treatment was identified. The first chelating agent introduced in 1951 for the treatment of WD was British anti-lewisite (BAL or dimercaptopropanol).^{11,12} The identification and testing of an orally administered chelator, D-penicillamine, by John Walsh in 1956 revolutionized treatment of this disorder.¹³ Other treatment modalities have since been identified, including use of zinc salts to block enteral copper absorption and orthotopic liver transplantation, which may be lifesaving and curative for this disorder.

Clinical Features

Over the years diagnostic advances have enabled more systematic screening of individuals suspected to have WD prior to their development of neurologic symptoms. These include recognition of corneal Kayser-Fleischer

Abbreviations: WD, Wilson disease; MR, magnetic resonance imaging; NASH, nonalcoholic steatohepatitis; AST, aspartate aminotransferase; ALT, alanine aminotransferase; OLT, orthotopic liver transplantation.

From the ¹Division of Gastroenterology and Nutrition, Hospital for Sick Children, Toronto, Ontario, Canada; and ²The Mount Sinai Medical Center, Division of Liver Diseases and The Recanati/Miller Transplantation Institute, One Gustave L. Levy Place, Box 1633, New York, NY 10029.

Received March 10, 2003; accepted March 23, 2003.

Address reprint requests to: Eve A. Roberts, M.D., F.R.C.P., Division of Gastroenterology and Nutrition, Hospital for Sick Children, Room 8267, Black Family Foundation Wing, 555 University Ave., Toronto, Ontario M5G 1X8, Canada. E-mail: eroberts@sickkids.ca; michael.schilsky@mssm.edu; fax: 416-813-4972.

Copyright © 2003 by the American Association for the Study of Liver Diseases. 0270-9139/03/3706-0035\$30.00/0

doi:10.1053/jhep.2003.50252

Table 1. Relating to Quality of Evidence on Which Recommendation Is Based

Grade	Definition
I	Evidence from multiple well-designed randomized controlled trials each involving a number of participants to be of sufficient statistical power
II	Evidence from at least one large well-designed clinical trial with or without randomization, from cohort or case-control analytic studies, or well-designed meta-analysis
III	Evidence based on clinical experience, descriptive studies, or reports of expert committees
IV	Not rated

NOTE. These standardized guidelines of the Practice Guideline Committee of the American Association for the Study of Liver Diseases have been modified from the categories of the Infectious Diseases Society of America's Quality Standards.¹

rings,³ identification of reduced concentrations of ceruloplasmin in the circulation of most patients,¹⁴ and the ability to measure copper concentration in percutaneous liver biopsy specimens. More recently, molecular diagnostic studies have made it feasible to define patterns of haplotypes or polymorphisms of DNA surrounding *ATP7B*, which are useful for identification of first-degree relatives of newly diagnosed patients. In some patients disease-specific mutations on both alleles of chromosome 13 can be determined.

Patients with cirrhosis, neurologic manifestations, and Kayser-Fleischer rings are easily diagnosed as having WD because they resemble the original clinical description. The patient presenting with liver disease, who is at least 5 years old but under 40 years old, with a decreased serum ceruloplasmin and detectable Kayser-Fleischer rings has been generally regarded as having classic WD.¹⁵ However,

about half of the patients presenting with liver disease do not possess two of these criteria and pose a challenge in trying to establish the diagnosis.¹⁶ Moreover, as with other liver diseases, patients may present when their clinical disease is comparatively mild.

Because, at the current time, no single, widely available test permits *de novo* genetic diagnosis, a combination of clinical findings and biochemical testing is still necessary to establish the diagnosis of WD (see algorithm in Fig. 1). A molecular genetic strategy ("DNA testing") using haplotype analysis or direct mutation analysis may be effective in identifying affected siblings of probands.

Spectrum of Disease

The spectrum of liver disease encountered in patients with WD is summarized in Table 2. The type of the liver disease can be highly variable, ranging from asymptomatic with only biochemical abnormalities to fulminant hepatic failure. Children may be entirely asymptomatic, with hepatic enlargement or abnormal serum aminotransferases found only incidentally. Some patients have a brief clinical illness resembling an acute viral hepatitis, and others may present as clinically indistinguishable from autoimmune hepatitis. Some present with only biochemical abnormalities or histologic findings of steatosis on liver biopsy. Many patients present with signs of chronic liver disease and evidence of cirrhosis, either compensated or decompensated. Patients may present with isolated splenomegaly due to clinically inapparent cirrhosis with portal hypertension. WD may also present as fulminant hepatic failure with an associated Coombs-negative hemolytic anemia and acute renal failure. Some patients

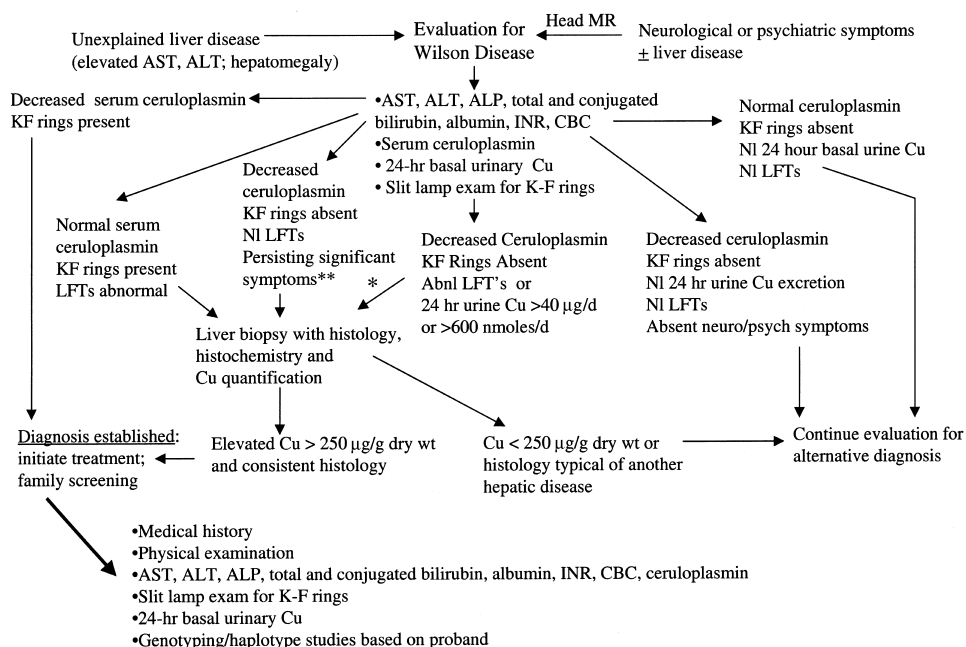


Fig. 1. Algorithm for assessment of suspected Wilson disease. Patients referred for unexplained liver disease typically have liver enlargement or abnormal serum aminotransferases; those with neurologic or psychiatric symptoms consistent with Wilson disease should have an MR scan of the head performed prior to the hepatologic evaluation. *For patients under 18 years, a penicillamine challenge test may be performed prior to liver biopsy. **Persisting significant symptoms include: hemolysis, unexplained splenomegaly, extrahepatic manifestations of WD (see Table 2), and neurologic or psychiatric disorders.

Table 2. Clinical Patterns of Hepatic, Neurologic, and Psychiatric Disease in Patients With WD

Hepatic	Asymptomatic hepatomegaly	
	Isolated splenomegaly	
	Persistently elevated serum aminotransferase activity (AST, ALT)	
	Fatty liver	
	Acute hepatitis	
	Resembling autoimmune hepatitis	
	Cirrhosis (compensated or decompensated)	
	Fulminant hepatic failure	
	Neurological	Movement disorders (tremor, involuntary movements)
		Drooling, dysarthria
Rigid dystonia		
Pseudobulbar palsy		
Seizures		
Migraine headaches		
Insomnia		
Psychiatric	Depression	
	Neuroses	
	Personality changes	
	Psychosis	
Other systems	Renal abnormalities: aminoaciduria and nephrolithiasis	
	Skeletal abnormalities: premature osteoporosis and arthritis	
	Cardiomyopathy, dysrhythmias	
	Pancreatitis	
	Hypoparathyroidism	
	Menstrual irregularities; infertility, repeated miscarriages	

have transient episodes of jaundice, due to hemolysis. Low-grade hemolysis may be associated with WD when liver disease is not clinically evident. In one series hemolysis was a presenting feature in 25 of 220 cases (12%); in these patients hemolysis occurred as a single acute episode, recurrently, or was low-grade and chronic.¹⁷ In a series of 283 Japanese cases of WD, only 3 presented with acute hemolysis alone,¹⁸ but one quarter of the patients who presented with jaundice also had hemolysis. Patients diagnosed with WD who have a history of jaundice may have previously experienced an episode of hemolysis.

Patients with apparent autoimmune hepatitis presenting in childhood, or in adults with a suspicion of autoimmune hepatitis that does not readily respond to therapy should be assessed carefully for WD because elevated serum immunoglobulins and detectable nonspecific autoantibodies may be found in both conditions.¹⁹⁻²¹

Neurologic manifestations of WD typically present later than the liver disease, most often in the third decade of life, but they can present in childhood. Earlier subtle findings may appear in pediatric patients, including changes in behavior, deterioration in schoolwork or inability to perform activities requiring good hand-eye coordination. Handwriting may deteriorate, and cramped small handwriting, as in Parkinson disease (micrographia), may develop. Other common findings in those presenting with neurologic disease include tremor, lack of motor coordination, drooling, dysarthria, dystonia, and

spasticity. Because of pseudobulbar palsy, transfer dysphagia may also occur, with a risk of aspiration if severe. Migraine headaches and insomnia may be reported; however, it is unclear whether seizures are more common. Along with behavioral changes, other psychiatric manifestations include depression, anxiety, and even frank psychosis. Many of the individuals with neurologic or psychiatric manifestations may have cirrhosis, but frequently they are not symptomatic from their liver disease.

Patients with WD may present with important extrahepatic manifestations apart from neurologic or psychiatric disease: renal abnormalities including aminoaciduria and nephrolithiasis,²²⁻²⁴ skeletal abnormalities such as premature osteoporosis and arthritis,²⁵ cardiomyopathy,²⁶⁻²⁸ pancreatitis,²⁹ hypoparathyroidism,³⁰ and infertility or repeated miscarriages.³¹⁻³⁴

Age

Even when presymptomatic siblings are excluded, the age at which WD may present or be diagnosed is both younger and older than generally appreciated, although the majority present between ages 5 and 35. The youngest patient reported with cirrhosis due to WD was 3 years old,³⁵ and others have been reported in the preschool age bracket including a 5-year-old child with fulminant hepatic failure.³⁶ The oldest patients with WD have been 55 to 62 years old at the time of diagnosis.^{37,38} Recently two siblings were diagnosed in their eighth decade, and the diagnosis was confirmed by molecular studies showing *ATP7B* mutations (Schilsky et al., unpublished observations). Although the upper age limit for consideration of WD is generally stated as less than 40 years, when other concurrent neurologic or psychiatric symptoms or histologic or biochemical findings suggest this disorder, further evaluation should be carried out even in older individuals.

Kayser-Fleischer Ring

Kayser-Fleischer rings represent deposition of copper in Descemet's membrane of the cornea. When they are visible by direct inspection, they appear as a band of golden-brownish pigment near the limbus. A slit-lamp examination by an experienced observer is required to identify Kayser-Fleischer rings in most patients. They are not entirely specific for WD, since they may be found in patients with chronic cholestatic diseases³⁹⁻⁴¹ and in children with neonatal cholestasis.⁴² Large series of patients with WD show that Kayser-Fleischer rings are present in only 50% to 62% of patients with mainly hepatic disease at the time of diagnosis.^{16,37,43-45} In children presenting with liver disease Kayser-Fleischer rings are usually absent.⁴⁶⁻⁴⁸ Kayser-Fleischer rings are almost invariably present in patients with a neurologic presentation, but

even in these patients they may not be found in 5%.^{16,49} Kayser-Fleischer rings are rarely identified in patients with other types of liver disease, typically chronic cholestatic liver diseases such as primary biliary cirrhosis and primary sclerosing cholangitis. These diseases can usually be distinguished from WD on clinical grounds.

Other ophthalmologic changes may be found. Sunflower cataracts, also found by slit-lamp examination, represent deposits of copper in the lens.⁵⁰ These typically do not obstruct vision. Both Kayser-Fleischer rings and sunflower cataracts will gradually disappear with effective medical treatment or following liver transplantation, although the rate of disappearance does not correlate with resolution of clinical symptoms.^{51,52} The reappearance of either of these ophthalmologic findings in a medically treated patient in whom these had previously disappeared suggests noncompliance with therapy.

Recommendations: (1) WD should be considered in any individual between the ages of 3 and 45 years with liver abnormalities of uncertain cause (III).

(2) In a patient in whom WD is suspected Kayser-Fleischer rings should be sought by slit-lamp examination by a skilled examiner. The absence of Kayser-Fleischer rings does not exclude the diagnosis of WD, even in patients with predominantly neurologic disease (III).

Diagnostic Testing

Biochemical Liver Tests

Serum aminotransferase activities are generally abnormal in WD except at a very early age. In many individuals, the degree of elevation of aminotransferase activity may be mild and does not reflect the severity of the liver disease.^{20,51}

Ceruloplasmin

This 132-kd protein is synthesized mainly in the liver and is an acute phase reactant. The vast majority of the protein is secreted into the circulation from hepatocytes as a copper-carrying protein containing 6 copper atoms per molecule of ceruloplasmin (holoceruloplasmin) and the remainder as the protein lacking copper (apoceruloplasmin). Ceruloplasmin functions as the major carrier for copper in the blood, accounting for 90% of the circulating copper in normal individuals. Ceruloplasmin also possesses activity as a ferroxidase⁵³ and acts as an oxidase for substrates such as *p*-phenylamine diamine⁵⁴ and *o*-dianisidine.⁵⁵ Levels of serum ceruloplasmin may be measured enzymatically by their copper-dependent oxidase activity towards these substrates, or by antibody-dependent assays such as radioimmunoassay, radial immunodiffusion, or nephelometry. Results generally are regarded as equivalent,⁵⁶ but immunologic assays may overestimate

ceruloplasmin concentrations since they do not discriminate between apoceruloplasmin and holoceruloplasmin. There are reports of the development of a monoclonal antibody that selectively discriminates between the two forms of ceruloplasmin, but this has never been successfully developed for use in clinical testing nor validated in populations with liver disease.⁵⁷⁻⁵⁹ Serum ceruloplasmin concentrations are elevated by acute inflammation, in states associated with hyperestrogenemia such as pregnancy, estrogen supplementation, and use of the oral contraceptive pill.

Levels of serum ceruloplasmin are physiologically very low in early infancy to the age of 6 months, peak at higher than adult levels in early childhood (at approximately 300-500 mg/L), and then settle to the adult range. Serum ceruloplasmin is typically decreased in patients with WD, but serum ceruloplasmin may be low in certain other conditions with marked renal or enteric protein loss or with severe end-stage liver disease of any etiology. Low levels of ceruloplasmin and/or pancytopenia have been recognized in patients with copper deficiency when trace elements were not added to parenteral alimentation,⁶⁰ and in patients with Menkes disease, an X-linked disorder of copper transport due to mutations in *ATP7A*.⁶¹ Patients with the rare disorder aceruloplasminemia lack the protein entirely due to mutations in the ceruloplasmin gene on chromosome 3, but these patients exhibit hemosiderosis, not copper accumulation.^{62,63}

A serum ceruloplasmin level less than 200 mg/L (<20 mg/dL, although there are different laboratory ranges) has been considered consistent with WD and diagnostic, if associated with Kayser-Fleischer rings. A prospective study of using serum ceruloplasmin alone as a screening test for WD in patients referred with liver disease showed that subnormal ceruloplasmin had a positive predictive value of only 6%: of 2,867 patients tested, only 17 had subnormal ceruloplasmin and only 1 of these was found to have WD.⁶⁴ Other recent reports indicate the scope of this problem. In one series, 12 of 55 WD patients had normal ceruloplasmin and no Kayser-Fleischer rings.¹⁶ In another study, 6 of 22 WD patients had serum ceruloplasmin greater than 170 mg/L (>17 mg/dL) and of these, 4 had no Kayser-Fleischer rings.³⁷ In children, 3 of 26 patients had ceruloplasmin greater than 150 mg/L (>15 mg/dL)⁴⁶ and in an early study 10 of 28 children with WD had serum ceruloplasmin \geq 200 mg/L (\geq 20 mg/dL).⁶⁵ Most reports based on several decades of experience from the mid-1950s onward indicate that 90% to 100% of patients had serum ceruloplasmin in the subnormal range.⁶⁶⁻⁶⁸ Using serum ceruloplasmin to identify patients with WD is further complicated by overlap with some

heterozygotes.⁶⁸ Approximately 20% of heterozygotes have decreased levels of serum ceruloplasmin.

Uric Acid

Serum uric acid may be decreased at presentation with symptomatic hepatic or neurologic disease because of associated renal tubular dysfunction (Fanconi syndrome). Insufficient evidence is available to determine the predictive value of this finding.

Recommendation: (3) Serum ceruloplasmin should be routinely measured during the evaluation of unexplained hepatic, neurologic, or psychiatric abnormalities in children and adults through middle age. An extremely low serum ceruloplasmin level (<50 mg/L or <5 mg/dL) should be taken as strong evidence for the diagnosis of WD. Modestly subnormal levels suggest that further evaluation is necessary. Serum ceruloplasmin within the normal range does not exclude the diagnosis (III).

Serum Copper

Although a disease of copper overload, the total serum copper (which includes copper incorporated in ceruloplasmin) in WD is usually decreased in proportion to the decreased ceruloplasmin in the circulation. In patients with severe liver injury, serum copper may be within the normal range despite a decreased serum ceruloplasmin level. In the setting of acute fulminant hepatic failure due to WD, levels of serum copper may be markedly elevated due to the sudden release of the metal from tissue stores. Normal or elevated serum copper levels in the face of decreased levels of ceruloplasmin indicate an increase in the concentration of copper not bound to ceruloplasmin in the blood (nonceruloplasmin-bound copper).

The serum nonceruloplasmin-bound copper concentration has been proposed as a diagnostic test for WD. It is elevated above 25 $\mu\text{g/dL}$ in most untreated patients (normal <15 $\mu\text{g/dL}$). Nonceruloplasmin-bound copper is usually estimated from the serum copper and ceruloplasmin. The amount of copper associated with ceruloplasmin is approximately 3.15 μg of copper per milligram of ceruloplasmin. Thus the nonceruloplasmin copper is the difference between the serum copper concentration in $\mu\text{g/dL}$ and 3 times the serum ceruloplasmin concentration in mg/dL .⁶⁹⁻⁷¹ (For SI units, both serum copper and ceruloplasmin should be expressed as *per liter*; the conversion factor is unchanged, but the normal reference value is <150 $\mu\text{g/L}$.) The serum nonceruloplasmin copper concentration may be elevated in acute liver failure of any etiology, not only WD,^{47,72} and it may be elevated in chronic cholestasis⁷³ and in cases of copper intoxication from ingestion or poisoning.

The major problem with nonceruloplasmin-bound copper as a diagnostic test for WD is that it is dependent on the adequacy of the methods for measuring both serum copper and ceruloplasmin. Therefore it is often difficult to interpret. It is of more value in patient monitoring of pharmacotherapy than in the diagnosis of WD. Unclear results should be correlated with the 24-hour urinary copper excretion. Nonceruloplasmin-bound copper concentration <5 $\mu\text{g/dL}$ in combination with exceedingly low 24-hour urinary copper excretion may signal systemic copper depletion that can occur in some patients with prolonged treatment.

Urinary Copper Excretion

The amount of copper excreted in the urine in a 24-hour period may be helpful for diagnosing WD and for monitoring of treatment. The 24-hour urinary excretion of copper reflects the amount of nonceruloplasmin-bound copper in the circulation. Basal measurements can provide useful diagnostic information so long as copper does not contaminate the collection apparatus and the urine collection is complete. There is too much variability in the copper content in spot urine specimens for them to be utilized. Volume and total creatinine excretion in the 24-hour urine collection are measured to assess completeness. The conventional level taken as diagnostic of WD is greater than 100 $\mu\text{g}/24$ hours (>1.6 $\mu\text{moles}/24$ hours) in symptomatic patients.⁷² Recent studies indicate that basal 24-hour urinary copper excretion may be less than 100 μg at presentation in 16% to 23% of patients diagnosed with WD.^{16,46,48} The reference limits for normal 24-hour excretion of copper vary among clinical laboratories. Many laboratories take 40 μg (0.6 μmoles) per 24 hours as the upper limit of normal. This appears to be a better threshold for diagnosis.^{37,74}

Interpreting 24-hour urinary copper excretion can be difficult due to overlap with findings in other types of liver disease, and heterozygotes may also have intermediate levels.⁷² Patients with certain chronic liver diseases, including autoimmune hepatitis, may have basal 24-hour copper excretion in the 100 to 200 $\mu\text{g}/24$ hours (1.6 - 3.2 $\mu\text{moles}/24$ hours) range.⁷⁵ In one study of patients with chronic active liver disease, 5 of 54 patients had urinary copper excretions above 100 $\mu\text{g}/24$ hours⁴³; overlap has also been found in children with autoimmune hepatitis.⁶⁵

Urinary copper excretion with D-penicillamine administration may be a useful diagnostic adjunctive test. This test has only been standardized in a pediatric population⁴⁷ in which 500 mg of D-penicillamine was administered orally at the beginning and again 12 hours later during the 24-hour urine collection irrespective of body weight. Compared with a spectrum of other liver diseases includ-

ing autoimmune hepatitis, primary sclerosing cholangitis, and acute liver failure, a clear differentiation was found when greater than 1,600 μg copper/24 hours (>25 $\mu\text{moles}/24$ hours) was excreted. This test has been used in adults, but many of the reported results of this test in adults utilized different dosages and timing for administration of the D-penicillamine.^{16,72,75}

Measurement of the basal 24-hour urinary excretion of copper forms part of the assessment to screen siblings for WD, but it has not been validated as the sole test for screening.

Recommendations: (4) The basal 24-hour urinary excretion should be measured as an aid to the diagnosis of WD. Basal 24-hour urinary excretion of copper in WD is typically greater than 100 μg (1.6 μmoles) in symptomatic patients, but a finding greater than 40 μg (>0.6 μmoles or >600 nmoles) may indicate WD and requires further investigation (II).

(5) In children, penicillamine challenge studies may provide evidence for the diagnosis of WD if urinary excretion of greater than 1,600 μg copper/24 hours (>25 $\mu\text{moles}/24$ hours) is found following the administration of 500 mg of D-penicillamine at the beginning and again 12 hours later during the 24-hour urine collection. The predictive value of this test in adults is unknown (II).

Hepatic Parenchymal Copper Concentration

Hepatic copper content ≥ 250 $\mu\text{g}/\text{g}$ dry weight remains the best biochemical evidence for WD. Normal concentrations rarely exceed 50 $\mu\text{g}/\text{g}$ dry weight of liver. The concentration of hepatic copper in heterozygotes, although frequently elevated above normal, does not exceed 250 $\mu\text{g}/\text{g}$ dry weight. In long-standing cholestatic disorders, hepatic copper content may also be increased above this level. Markedly elevated levels of hepatic copper may also be found in idiopathic copper toxicosis syndromes such as Indian childhood cirrhosis.⁴⁷

Biopsies for quantitative copper determination should be taken with a disposable Jamshidi or Tru-Cut needle and placed dry in a copper-free container. A core (or part of a biopsy core) of liver should be dried overnight in a vacuum oven or, preferably, frozen immediately and kept frozen for shipment to a laboratory for quantitative copper determination. Paraffin-embedded specimens can also be analyzed for copper content.

The major problem with hepatic parenchymal copper concentration is that in later stages of WD, distribution of copper within the liver is often inhomogeneous. In extreme cases nodules lacking histochemically detectable copper are found next to the cirrhotic nodule with abundant copper. Thus, the concentration can be underestimated due to sampling error. In a pediatric study,

sampling error was sufficiently common to render this test unreliable in patients with cirrhosis and clinically evident WD.⁴⁷ In general, the accuracy of measurement is improved with adequate specimen size: at least 1 cm of biopsy core length should be submitted for analysis.⁷⁶ Technical problems associated with obtaining a liver biopsy in a patient with decompensated cirrhosis or severe coagulopathy have largely been circumvented by the advent of the transjugular liver biopsy. However, the measurement of hepatic parenchymal copper concentration is most important in younger patients in whom hepatocellular copper is mainly cytoplasmic and thus undetectable by routine histochemical methods.

Radiocopper Study

In WD patients with a normal serum ceruloplasmin, radiocopper incorporation into this protein is significantly reduced compared with normal individuals and most heterozygotes. The failure to incorporate copper into the plasma protein within the hepatocyte occurs in all homozygotes with the disease. This test is now rarely used because of the difficulty in obtaining isotope. An experimental alternative to using radiocopper is the use of a nonradioactive isotope for copper, ⁶⁵Cu, which can be detected by mass spectroscopic methods⁷⁷; however, this methodology has difficulty in distinguishing heterozygotes from patients and is not routinely available.

Recommendation: (6) Hepatic parenchymal copper content greater than 250 $\mu\text{g}/\text{g}$ dry weight provides critical diagnostic information and should be obtained in cases where the diagnosis is not straightforward and in younger patients. In untreated patients, normal hepatic copper content (<40 to 50 $\mu\text{g}/\text{g}$ dry weight) excludes a diagnosis of WD (III).

Liver Biopsy Findings

The earliest histologic abnormalities in the liver include mild steatosis (both microvesicular and macrovesicular), glycogenated nuclei in hepatocytes, and focal hepatocellular necrosis.^{78,79} The liver biopsy may show classic histologic features of autoimmune hepatitis (the so-called "chronic active hepatitis" picture). With progressive parenchymal damage, fibrosis and subsequently cirrhosis develop.⁸⁰ Cirrhosis is frequently found in most patients by the second decade. It is usually macronodular, although occasionally micronodular. There are some older individuals who do not appear to have cirrhosis even after this time, although they have neurologic disease; however, their hepatic histology is not normal.¹⁶ In the setting of fulminant hepatic failure, there is marked hepatocellular degeneration and parenchymal collapse, typically on the background of cirrhosis. Apoptosis of

hepatocytes is a prominent feature during the acute fulminant injury.⁸¹

Detection of copper in hepatocytes by routine histochemical evaluation is highly variable. In early stages of the disease, copper is mainly in the cytoplasm bound to metallothionein and is not histochemically detectable; later, copper is found predominantly in lysosomes.⁸² The amount of copper varies from nodule to nodule in cirrhotic liver and may vary from cell to cell in precirrhotic stages. The absence of histochemically identifiable copper does not exclude WD, and for screening for WD this test has a poor predictive value.⁸³ Copper-binding protein can be stained by various methods including the rhodanine or orcein stain. The more sensitive Timms sulphur stain for copper binding protein is not routinely applied.⁸²

Ultrastructural analysis of liver specimens at the time steatosis is present reveals specific mitochondrial abnormalities.^{84,85} Specific patterns of mitochondrial abnormalities may be visible among affected family members.⁸⁶ Typical findings include variability in size and shape, increased density of the matrix material, and numerous inclusions including lipid and fine granular material that may be copper.⁸⁷ The most striking alteration is increased intracrystal space with dilatation of the tips of the cristae, creating a cystic appearance. In the absence of cholestasis, these changes are considered to be essentially pathognomonic of WD. With adequate chelation treatment, these changes may resolve.⁸⁸ At later stages of the disease, dense deposits within lysosomes are present. Ultrastructural analysis may be a useful adjunct for diagnosis in helping to distinguish between heterozygous carriers and patients, but if not routine, it requires advanced planning so that part of the specimen is placed in the proper preservative when biopsy is performed.

Development of hepatocellular carcinoma is a rarely reported complication of WD.⁸⁹⁻⁹¹ Screening for hepatocellular carcinoma has not been recommended for WD patients; however, objective data are lacking and the cost effectiveness of screening in this population needs to be examined prospectively for those with cirrhosis at the time of presentation.

Neurologic Findings and Radiologic Imaging of the Brain

Neurologic disease may manifest as motor abnormalities with Parkinsonian characteristics of dystonia, hyper-tonia, and rigidity, choreic or pseudosclerotic, with tremors and dysarthria. Disabling symptoms include muscle spasms, which can lead to contractures, dysarthria and dysphonia, and dysphagia. At this stage of disease, magnetic resonance imaging (MR) of the brain or computerized tomography may detect structural abnormali-

ties in the basal ganglia. Most frequently found are increased density on computerized tomography and hyperintensity on T2 MR imaging in the region of the basal ganglia. MR may be more sensitive in detecting these lesions. Abnormal findings are not limited to this region, and other abnormalities have been described. Significant abnormalities on brain imaging may even be present in some individuals prior to the onset of symptoms.^{92,93}

Neurologic evaluation should be performed on all patients with WD. Consultation with a neurologist or movement disorder specialist should be sought for evaluation of patients with evident neurologic symptoms before treatment or soon after treatment is initiated. A specific rating scale based on that for Huntington disease was used to evaluate patients with WD in clinical trials; however, this has never been tested outside of this research setting.^{94,95}

Recommendation: (7) Neurologic evaluation and radiologic imaging of the brain, preferably by MR, should be considered prior to treatment in all patients with neurologic WD and should be part of the evaluation of any patient presenting with neurologic symptoms consistent with WD (III).

Genetic Studies

Molecular genetic studies are becoming available for clinical use, but only pedigree analysis using haplotypes based on polymorphisms surrounding the WD gene is commercially available from specific clinical laboratories. This analysis requires the identification of a patient within the family (the proband) by clinical and biochemical studies as above. After the mutation or haplotype, based on the pattern of di- and trinucleotide repeats around *ATP7B*, is determined in the proband, the same specific regions of the DNA from first-degree relatives can be tested to determine whether or not they are unaffected, heterozygous, or indeed patients.⁹⁶⁻⁹⁹ Prenatal testing can also be performed^{100,101} but has limited application clinically since diagnosis early in life allows appropriate timing for treatment.⁵⁹

The utility of direct mutation analysis is currently limited since most patients are compound heterozygotes with a different mutation on each allele, and currently over 200 mutations of *ATP7B* have been identified (see www.medgen.med.ualberta.ca/database.html for updated catalogue). *De novo* diagnoses by molecular studies remain difficult at present due to the large numbers of disease-specific mutations of *ATP7B*, and with current methodology analysis remains labor intensive and tedious. Mutation analysis is a valuable but not readily available diagnostic strategy for certain well-defined populations exhibiting a limited spectrum of *ATP7B* mutations. Some

populations with a single predominant mutation include Sardinian,¹⁰² Icelandic,¹⁰³ Korean,¹⁰⁴ Japanese,¹⁰⁵ and in the Canary Islands.⁷⁴ Certain populations in Eastern Europe also show predominance of the H1069Q mutation.^{106,107}

Genotype to phenotype correlations in WD are hampered by the high prevalence of compound heterozygotes, patients with WD who carry one each of two different mutations in *ATP7B*. Studies in homozygotes suggest that mutations affecting critical portions of the protein including copper-binding domains or the ATPase loop may lead to early onset of hepatic disease,¹⁰⁸ but strict concordance is difficult to prove.^{99,109}

Recommendation: (8) When possible, genetic diagnosis based on haplotype analysis should be used for family screening of first-degree relatives of patients with WD (III).

Diagnostic Considerations in Specific Target Populations

"Mimic" Liver Diseases

Patients with WD, especially younger ones, may have clinical features and histologic findings on liver biopsy indistinguishable from autoimmune hepatitis.¹⁹⁻²¹ All children with apparent autoimmune hepatitis and any adult patient with the presumptive diagnosis of autoimmune hepatitis failing to respond rapidly and appropriately to corticosteroid treatment must be carefully evaluated for WD. Occasional patients with WD may benefit from a brief course of treatment with corticosteroids along with appropriate specific treatment for WD.²¹ Hepatic steatosis in WD is rarely as severe as in nonalcoholic steatohepatitis (NASH). Nevertheless occasional patients with WD resemble NASH convincingly or may have both diseases.

Fulminant Liver Failure

Most patients with the fulminant hepatic failure presentation of WD have a characteristic pattern of clinical and biochemical findings¹¹⁰⁻¹¹⁵:

1. Coombs-negative hemolytic anemia with features of acute intravascular hemolysis
2. Coagulopathy unresponsive to parenteral vitamin K administration
3. Rapid progression to renal failure
4. Relatively modest rises in serum aminotransferases (typically <2,000 IU/L) from the beginning of clinical illness
5. Normal or markedly subnormal serum alkaline phosphatase (typically <40 IU/L)¹¹⁶
6. Female to male ratio of 2:1

A high level of clinical suspicion is essential for the diagnosis; simple indices of laboratory findings do not reliably distinguish patients with fulminant hepatic failure from those with acute liver failure due to viral infection or drug toxicity.¹¹⁷ The relatively modest elevations of serum aminotransferase activity seen in most of these individuals compared with acute liver failure of other etiologies often leads to an underestimate of the severity of the disease. Serum ceruloplasmin is usually decreased; serum copper and 24-hour urinary excretion of copper are greatly elevated. In many facilities these results are not available in a timely manner, and diagnosis has to rest on clinical features. Kayser-Fleischer rings may be identified to support the diagnosis of WD but may be absent in 50% of these patients. Other findings, such as lunulae ceruleae, are rarely detected but should suggest further evaluation to exclude WD. Expedient diagnosis is critically important since these patients require urgent liver transplantation to survive. In some patients with fulminant hepatic failure, the serum aspartate aminotransferase (AST) level may be higher than the serum alanine aminotransferase (ALT) level, potentially reflecting mitochondrial damage, but this finding is not sufficiently invariable to be diagnostic.^{45,51,118,119} A more common finding in this setting is the low level of serum alkaline phosphatase activity and a ratio of alkaline phosphatase (IU/L) to total bilirubin (in mg/dL) of less than 2.¹¹⁹ A prognostic index to be applied at the time of diagnosis of acute fulminant WD that may be helpful to predict survival without liver transplantation has been developed based on total serum bilirubin, AST, and prolongation of prothrombin time¹²⁰; although it defines extreme cases adequately, it does not discriminate between survivors and nonsurvivors in patients with moderately severe disease reliably.

Because this is usually the first presentation of WD in the patient, underlying liver disease is not suspected, although cirrhosis is typically present.⁴⁵ It is thought that an intercurrent illness such as a viral infection¹²¹ or drug toxicity may touch off this rapidly progressive liver disease. Rare patients have acute liver failure from viral hepatitis and are found at that time to have underlying WD.^{122,123}

Recommendations: (9) Patients in the pediatric age bracket who present a clinical picture of autoimmune hepatitis should be investigated for WD. Adult patients with atypical autoimmune hepatitis or who respond poorly to standard corticosteroid therapy should also be investigated for WD (III).

(10) WD should be considered in the differential diagnosis of patients presenting with nonalcoholic fatty liver or who have pathologic findings of NASH (IV).

(11) WD should be suspected in any patient presenting with fulminant hepatic failure with Coombs-negative intravascular hemolysis, modest elevations in serum aminotransferases, low serum alkaline phosphatase, and ratio of alkaline phosphatase to bilirubin of less than 2 (III).

Family Screening

First-degree relatives of any patient newly diagnosed with WD must be screened for WD. Assessment should include brief history relating to jaundice, liver disease, and subtle features of neurologic involvement; physical examination; serum copper, ceruloplasmin, and liver function tests including aminotransferases, albumin, conjugated and unconjugated bilirubin; slit-lamp examination of the eyes for Kayser-Fleischer rings; and measurement of basal 24-hour urinary copper. Individuals without Kayser-Fleischer rings who have subnormal ceruloplasmin and abnormal liver functions should undergo liver biopsy to confirm the diagnosis. If available, haplotype studies should be obtained and may be used as primary screening. Treatment should be initiated for all individuals over 3 to 4 years old identified as patients by family screening.

Recommendation: (12) First-degree relatives of any patient newly diagnosed with WD must be screened for WD. Assessment should include history and physical examination, serum aminotransferases and biochemical tests of hepatic synthetic function, complete blood count, and ceruloplasmin. Kayser-Fleischer rings should be sought by slit-lamp examination. The basal 24-hour urinary copper excretion should be measured. Genotype or haplotype studies based on findings in the proband should be performed (II).

Treatment

For the first half a century following the description of WD there was no effective treatment for this progressively fatal disorder. Since controlled trials were not possible when treatment became available, treatments for WD historically progressed from the intramuscular administration of BAL to the more easily administered oral penicillamine. Although there are studies showing dose response of penicillamine and the resultant cupriuresis, initial clinical use was limited by the availability of the drug itself and empiric doses were chosen because no formal dose response studies for efficacy over time were carried out. Interestingly, when these treatments initially became available, treatment was first reserved for symptomatic patients because there were no good diagnostic tests available to identify presymptomatic disease. Simultaneous with the advances in diagnostic testing for WD, a new era was ushered in by the recognition that significant morbidity and mortality could be prevented by the treat-

ment of asymptomatic patients.¹²⁴ The development of alternative agents to penicillamine was stimulated by the inability of some patients to tolerate this drug. Trientine was developed and introduced specifically for patients who developed adverse reactions to penicillamine. Zinc was developed separately, as was tetrathiomolybdate, which was used by veterinarians for copper poisoning in animals. Today, the mainstay of treatment for WD remains lifelong pharmacologic therapy; liver transplantation, which corrects the underlying hepatic defect in WD, is reserved for severe or resistant cases.

In general, the approach to treatment is dependent on whether there is active disease or symptoms, whether neurologic or hepatic, or whether the patient is identified prior to the onset of clinical symptoms. We believe this distinction helps in determining the choice of therapy and the dosages of medications utilized, although there are no studies in which this approach has been systematically explored. The recommended initial treatment of symptomatic patients or those with active disease is with chelating agents, although there are some reports showing that primary treatment with zinc may be adequate for some individuals. The largest treatment experience worldwide is still with D-penicillamine; however, there is now more frequent consideration of trientine for primary therapy. Data now exist showing the efficacy of trientine when treating patients with decompensated neurologic or hepatic disease. Previous limitations to the use of trientine were its limited supply and concerns about its continued availability; many clinicians lack experience with this medication. Combination therapy, in which zinc is utilized in conjunction with a chelating agent (temporally separated), has a theoretical basis in both blocking copper uptake and eliminating excess copper. There are only preliminary reports of the simultaneous use of chelators and zinc as primary therapy, and future studies are needed to determine whether efficacy is greater than with therapy with a chelator alone. Studies of the use of tetrathiomolybdate as an alternative chelating agent for the initial treatment of neurologic WD are ongoing.

Once disease symptoms or biochemical abnormalities have stabilized, typically 2 to 6 months following initiation of therapy,²⁰ maintenance dosages of chelators or zinc therapy can be used for treatment. Patients presenting without symptoms may be treated with either maintenance dosages of a chelating agent or with zinc from the outset. Failure to comply with lifelong therapy has led to recurrent symptoms and liver failure, the latter requiring liver transplantation for survival. Monitoring of therapy includes monitoring for compliance as well as for potential treatment-induced side effects.

Table 3. Pharmacologic Treatment Modalities for WD

Drug	Mode of Action	Neurologic Deterioration?	Side Effects	Comments
D-penicillamine	General chelator: induces cupriuria	10% to 50% during initial phase of treatment	Fever, rash, proteinuria, lupus-like reaction Aplastic anemia Leukopenia Thrombocytopenia Nephrotic syndrome Degenerative changes in skin Elastosis perforans serpiginosa Serous retinitis Hepatotoxicity	Reduce dose for surgery to promote wound healing and during pregnancy
Trientine	General chelator: induces cupriuria	Occasionally during initial phase of treatment	Gastritis Aplastic anemia rare Sideroblastic anemia	Reduce dose for surgery to promote wound healing and during pregnancy
Zinc	Metallothionein inducer: blocks intestinal absorption of copper	During initial phase of treatment	Gastritis; biochemical pancreatitis Zinc accumulation Possible changes in immune function	No dosage reduction for surgery or pregnancy
Tetrathiomolybdate	General chelator: blocks copper absorption, induces intestinal and urinary copper loss	Reports of only rare neurologic deterioration during initial treatment	Anemia; neutropenia	Experimental in the United States and Canada

Available Treatments (Table 3)

D-Penicillamine. Penicillamine was introduced as the first oral agent for treating WD in 1956.¹³ It was identified as a breakdown product of penicillin but is actually the sulfhydryl-bearing amino acid cysteine doubly substituted with methyl groups. Like dimercaptopropanol (British anti-lewisite, or BAL) it has a free sulfhydryl group, which functions as the copper chelating moiety. Penicillamine is currently synthesized as such, and contamination with penicillin is not an issue; likewise, the racemic mixture, which tends to interfere with pyridoxine action, is no longer used.

The major effect of penicillamine in WD is to promote the urinary excretion of copper. Penicillamine may also act by inducing metallothionein in individuals with WD.¹²⁵ Penicillamine also interferes with collagen cross-linking¹²⁶ and has some immunosuppressant actions.¹²⁷ It is a general chelator of metals, is used to treat cystinosis, and has been used as an immunosuppressant in rheumatoid arthritis.

Penicillamine is rapidly absorbed from the gastrointestinal tract with a double-peaked curve for intestinal absorption.¹²⁸⁻¹³⁰ Uptake may occur by an unusual mechanism: disulfide binding to the enterocyte membrane followed by pinocytosis. If taken with a meal, absorption of the drug is decreased overall by about 50%.^{130,131} Total bioavailability is estimated at 40% to 70%.^{129,132} Once absorbed, 80% of penicillamine circulates bound to plasma proteins; there is little free penicillamine in the plasma, as it forms inactive dimers or binds to cysteine. Over 80% of penicillamine excretion is via the

kidneys. The excretion half-life of penicillamine is on the order of 1.7-7 hours,^{128,130,132} but there is considerable interindividual variation, and penicillamine or its metabolites can be found in the urine months after the drug has been discontinued.¹³³

The initial use of penicillamine was for the treatment of symptomatic patients, and numerous studies attest to the effectiveness of penicillamine as treatment for WD.^{66,134-139} Worsening of neurologic symptoms has been reported in 10% to 50% of those treated with penicillamine during the initial phase of treatment.^{140,141} For patients with symptomatic liver disease, the time for evidence of recovery of synthetic function and improvement in clinical signs such as jaundice and ascites is typically during the first 2 to 6 months of treatment, but further recovery can occur during the first year of treatment.³³ Failure to comply with therapy has led to significant progression of liver disease and liver failure in 1 to 12 months following discontinuation of treatment, resulting in death or necessitating liver transplantation.¹⁴²

Penicillamine use is associated with numerous side effects. Severe side effects requiring the drug to be discontinued occur in 20% to 30% of patients. Early sensitivity reactions marked by fever and cutaneous eruptions, lymphadenopathy, neutropenia or thrombocytopenia, and proteinuria may occur during the first 1 to 3 weeks. Penicillamine should be discontinued immediately if early sensitivity occurs; the availability of alternative medications makes a trial of prednisone cotreatment unnecessary. Late reactions include nephrotoxicity, usually heralded by proteinuria or the appearance of other cellular

elements in the urine, for which discontinuation of penicillamine should be immediate. Other late reactions include a lupus-like syndrome marked by hematuria, proteinuria, positive antinuclear antibody, and with higher dosages of penicillamine no longer typically used for treating WD, Goodpasture syndrome. Significant bone marrow toxicity includes severe thrombocytopenia or total aplasia. Dermatologic toxicities reported include progeric changes in the skin and elastosis perforans serpiginosa, and pemphigus or pemphigoid lesions, lichen planus, and aphthous stomatitis. Very late side effects include nephrotoxicity, severe allergic response upon restarting the drug after it has been discontinued, myasthenia gravis, polymyositis, loss of taste, IgA depression, and serous retinitis. Hepatotoxicity has been reported.¹⁴³ Hepatic siderosis has been reported in association with treated patients with reduced levels of serum ceruloplasmin and nonceruloplasmin-bound copper.¹⁴⁴

Tolerability of penicillamine may be enhanced by starting with incremental doses, 250 to 500 mg/d, increased by 250 mg increments every 4 to 7 days to a maximum of 1,000 to 1,500 mg/d in 2 to 4 divided dosages. Maintenance dose is usually 750 to 1,000 mg/d administered in 2 divided doses. Dosing in the child is 20 mg/kg/d rounded off to the nearest 250 mg and given in 2 or 3 divided doses. Penicillamine is best administered 1 hour prior to or 2 hours after meals as food inhibits its absorption. Closer proximity to meals is acceptable if it ensures compliance. Apart from numerous adverse side effects detailed above, another feature of treatment with D-penicillamine is that the serum ceruloplasmin tends to decrease after initiation of treatment. Serum ceruloplasmin may either remain low or increase over the term of chronic treatment, the latter occurring in some patients with severe hepatic insufficiency as they recover synthetic function in response to treatment.

Adequacy of treatment is monitored by measuring 24-hour urinary copper excretion while on treatment. This should run in the vicinity of 200 to 500 μg (3-8 μmoles) per day on treatment. Regular supplementation with pyridoxine is required at a dose of 25 to 50 mg daily. In addition, estimate of nonceruloplasmin-bound copper shows normalization of the nonceruloplasmin-bound copper concentration with effective treatment.

Trientine. Trientine (triethylene tetramine dihydrochloride or 2,2,2-tetramine, also known by its official short name trien) is one of a family of chelators with a polyamine-like structure chemically distinct from penicillamine. It lacks sulfhydryl groups, and copper is chelated by forming a stable complex with the 4 constituent nitrogens in a planar ring.

Trientine was introduced in 1969 as an alternative to penicillamine. Few data exist about the pharmacokinetics of trientine. It is poorly absorbed from the gastrointestinal tract, and what is absorbed is metabolized and inactivated.^{145,146} About 1% of the administered trientine and about 8% of the biotransformed trientine metabolite, acetyltrien, ultimately appears in the urine. The acetyltrien is a less effective chelator than trien. The amounts of urinary copper, zinc, and iron increase in parallel with the amount of trientine that appears in the urine.¹⁴⁷

Like penicillamine, trientine promotes copper excretion by the kidneys. Whether trientine is a weaker chelator of copper than penicillamine is controversial,^{135,148,149} and dose adjustments can compensate for small differences. Trientine and penicillamine may mobilize different pools of body copper.¹⁴⁸

Trientine is an effective treatment for WD^{142,150} and is indicated especially in patients who are intolerant of penicillamine or have clinical features indicating potential intolerance (history of renal disease of any sort, congestive splenomegaly causing severe thrombocytopenia, or autoimmune tendency). Neurologic worsening after beginning treatment with trientine has been reported but appears much less common than with penicillamine. Trientine has also been shown to be an effective initial therapy for patients, even with decompensated liver disease at the outset.^{151,152}

Trientine has few side effects. No hypersensitivity reactions have been reported although a fixed drug reaction was observed in one patient. Pancytopenia has rarely been reported. Trientine also chelates iron, and their coadministration should be avoided since the complex with iron is toxic. A reversible sideroblastic anemia may be a consequence of over-treatment and resultant copper deficiency. Lupus-like reactions have also been reported in some WD patients treated with trientine; however, these patients were almost all uniformly treated previously with penicillamine, so the true frequency of this reaction when trientine is used *de novo* is unknown. In general adverse effects due to penicillamine resolve when trientine is substituted for penicillamine and do not recur during prolonged treatment with trientine. Use in patients with primary biliary cirrhosis revealed that trientine may cause hemorrhagic gastritis, loss of taste, and rashes.¹⁵³ Recent evidence suggests that copper deficiency induced by trientine can result in iron overload in livers of patients with WD, similar to that observed for penicillamine.¹⁵⁴

Typical dosages are 750 to 1,500 mg/d in 2 or 3 divided doses, with 750 or 1,000 mg used for maintenance therapy. In children the weight-based dose is not established, but the dose generally used is 20 mg/kg/d rounded off to the nearest 250 mg, given in 2 or 3 divided doses. As

for penicillamine, trientine should be administered 1 hour before or 2 hours after meals. Taking it closer to meals is acceptable if this ensures compliance. Trientine tablets are not stable for prolonged periods at high ambient temperatures, a problem for patients traveling to warm climates.

Adequacy of treatment is monitored by measuring 24-hour urinary copper excretion while on treatment. This should run in the vicinity of 200 to 500 μg (3-8 μmoles) per day on treatment. Additionally, estimate of nonceruloplasmin-bound copper may show normalization of the nonceruloplasmin-bound copper concentration with effective treatment.

Zinc. Zinc was first used to treat WD by Schouwink in Holland in the early 1960s.^{155,156} Its mechanism of action is different from that of penicillamine and trientine: zinc interferes with the uptake of copper from the gastrointestinal tract. Zinc induces enterocyte metallothionein, a cysteine-rich protein that is an endogenous chelator of metals. Metallothionein has greater affinity for copper than for zinc and thus preferentially binds copper present in the enterocyte and inhibits its entry into the portal circulation. Once bound, the copper is not absorbed but is lost into the fecal contents as enterocytes are shed in normal turnover.¹⁵⁷ Since copper also enters the gastrointestinal tract from saliva and gastric secretions, zinc treatment can generate a negative balance for copper and thereby remove stored copper.¹⁵⁸ Zinc may also act by inducing levels of hepatocellular metallothionein.¹⁵⁹⁻¹⁶¹

Zinc has very few side effects. Gastric irritation is the main problem and may be dependent on the salt employed. Hepatic deterioration has been occasionally reported when zinc was commenced, fatal in one case.^{162,163} Zinc may have immunosuppressant effects and reduce leukocyte chemotaxis, but one study found no adverse effect on lymphocyte function with chronic use.¹⁶⁴ Elevations in serum lipase and/or amylase may occur, without clinical or radiologic evidence of pancreatitis. Neurologic deterioration is uncommon with zinc.^{139,157} Whether high-dose zinc is safe for patients with impaired renal function is not yet established.

Although zinc is currently reserved for maintenance treatment, it has been used as first-line therapy, most commonly for asymptomatic or presymptomatic patients. It appears to be equally effective as penicillamine but much better tolerated.¹³⁹ Reports of extensive series of adults with WD indicate good efficacy.^{95,156} A child who presented with ascites and coagulopathy was effectively treated only with zinc¹⁶⁵; a few other favorable reports in children have appeared.^{166,167} Combination treatment with trientine plus zinc or penicillamine plus zinc in which the chelator and the zinc are given at widely spaced

intervals during the day has been advocated but not yet reported in rigorously designed series.

Dosing is in milligrams of *elemental* zinc. For larger children and adults, 150 mg/d is administered in 3 divided doses. Compliance with the 3 times per day dosage may be problematic, and it has to be taken at least twice daily to be effective.⁹⁵ The actual salt used does not make a difference with respect to efficacy but may affect tolerability. Acetate may cause the least gastrointestinal distress, and gluconate may be more tolerable than sulfate. For smaller children less than 50 kg in body weight, the dose is 75 mg/d in 3 divided doses,¹⁶⁸ and dose is poorly determined for children under 5 years of age. Taking zinc with food interferes with zinc absorption¹⁶⁹ and effectiveness of treatment, but dose adjustments can be employed to compensate for this effect if taking zinc around meal-time ensures compliance.

Adequacy of treatment with zinc is judged by clinical and biochemical improvement and by measuring 24-hour urinary excretion of copper, which should be less than 75 μg (1.2 μmoles) per 24 hours on stable treatment. Additionally, estimate of nonceruloplasmin-bound copper shows normalization of the nonceruloplasmin-bound copper concentration with effective treatment. Urinary excretion of zinc may be measured from time to time to check compliance.

Antioxidants. Antioxidants, mainly vitamin E, may have a role as adjunctive treatment. Serum and hepatic vitamin E levels have been found to be low in WD.¹⁷⁰⁻¹⁷² Symptomatic improvement when vitamin E was added to the treatment regimen has been occasionally reported but no rigorous studies have been conducted.

Diet. Foods with very high concentrations of copper (shellfish, nuts, chocolate, mushrooms, and organ meats) generally should be avoided, at least in the first year of treatment. Diets deficient in copper may delay the onset of the disease and control disease progression, but dietary management is not recommended as sole therapy.¹⁷³ Consultation with a dietitian is advisable for practicing vegetarians. Well water or water brought into the household through copper pipes should be checked for copper content, but in general, municipal water supplies do not have to be checked. A water purifying system may be advisable if the copper content of the water is high. For those with copper pipes, it is important to flush the system of stagnant water before using water for cooking or consumption.

Recommendations: (13) Initial treatment for symptomatic patients should include a chelating agent (penicillamine or trientine) (II).

(14) Treatment of presymptomatic patients or maintenance therapy of successfully treated symptomatic pa-

tients can be accomplished with the chelating agent penicillamine or trientine, or with zinc (II).

Tetrathiomolybdate. Tetrathiomolybdate is another chelating agent currently undergoing evaluation as an initial treatment of patients with neurologic symptoms. The first reports on the use of tetrathiomolybdate in this setting suggest no worsening of neurologic symptoms and a rapid reduction in circulating nonceruloplasmin-bound copper during the first 8 weeks of therapy.^{94,174} Currently this medication remains experimental in the United States and it is not commercially available.

Treatment in Specific Clinical Situations

Asymptomatic Patients. For asymptomatic or presymptomatic patients identified through family screening, treatment with a chelating agent, such as D-penicillamine^{124,175} or with zinc is effective in preventing disease symptoms or progression.¹⁷⁶ Whether D-penicillamine or zinc should be used in presymptomatic children under the age of 3 years has not been determined.

Maintenance Therapy. After adequate treatment with a chelator, stable patients may be transitioned to treatment with zinc. In general, such patients will have been treated for 1 to 5 years. They will be clinically well, with normal serum aminotransferases and hepatic synthetic function, nonceruloplasmin-bound copper concentration in normal range, and 24-hour urinary copper repeatedly in the range of 200 to 500 μg (3–8 μmoles) per day on treatment. The advantages of long-term treatment with zinc include that it is more selective for removing copper than penicillamine or trientine and is associated with few side effects. Adequate studies regarding the timing of this change-over in treatment are not available. No matter how well a patient appears, treatment should never be terminated indefinitely. Patients who discontinue treatment altogether risk development of intractable hepatic decompensation.^{142,177}

Fulminant Hepatic Failure. Patients with fulminant hepatic failure due to WD require liver transplantation, which is life saving.¹⁷⁸ To help determine which patients with acute hepatic presentations will not survive without liver transplantation, Nazer et al. developed a prognostic score whose components include serum bilirubin, serum AST, and prolongation of prothrombin time above normal; patients with a score of 7 or greater did not survive in their series of patients with WD.¹²⁰ Until transplantation can be performed, plasmapheresis and exchange transfusion¹⁷⁹ or hemofiltration¹⁸⁰ or dialysis may protect the kidneys from copper-mediated tubular damage.^{181,182} Albumin dialysis was shown to stabilize patients with fulminant hepatic failure due to WD and delay, but not eliminate, the need for transplantation.¹⁸³ The MARS

ultrafiltration device may also be efficacious in this setting.^{184,185}

Pregnancy. In pregnant women, treatment must be maintained throughout the course of pregnancy for all patients with WD. Interruption of treatment during pregnancy has resulted in fulminant hepatic failure.¹⁸⁶ Experience to date indicates that the chelating agents (both penicillamine and trientine)^{146,187–190} and zinc salts^{191,192} have been associated with satisfactory outcomes for the mother and fetus.^{34,193–197} The occurrence of a few birth defects has been noted infrequently in offspring of treated patients; however, the rarity of this disorder has made it difficult to determine whether this is different from the frequency for the occurrence of these defects in the population at large. The dosage of zinc salts is maintained throughout without change; however, dosages of chelating agents should be reduced to the minimum necessary during pregnancy, especially for the last trimester, to promote better wound healing if cesarean section is performed. Such a dose reduction might be on the order of 25% to 50% of the prepregnancy dose.

Liver Transplantation. Orthotopic liver transplantation (OLT) is indicated for all WD patients with decompensated liver disease unresponsive to medical therapy, and it is the only effective option for those who present with fulminant hepatic failure. OLT corrects the hepatic metabolic defects of WD and may serve to initiate normalization of extrahepatic copper disposition.¹⁹⁸ One-year survival following OLT ranges from 79% to 87%, and those who survive this early period continue to survive long term.¹⁹⁹ While the vast majority of patients undergoing liver transplantation for WD have received cadaveric donor organs, living donor transplantations can be performed. In one study it was found that successful live donor transplantation was possible even when the donor is a family member heterozygous for WD.²⁰⁰

Less definite indications for OLT exist for patients with respect to severe neurologic disease. Some individuals transplanted for decompensated cirrhosis have had psychiatric or neurologic symptoms, which improved following OLT.^{199,201} There are also a few reports of other individuals transplanted for neurologic disease that improved after OLT,^{202–205} but detailed data on the neurologic evaluations of these patients are not available. Liver transplantation is not recommended as primary treatment for neurologic WD since the liver disease is stabilized by medical therapy in most of these individuals, and outcomes with liver transplantation are not always beneficial.^{45,51,199,206–208}

Recommendations: (15) Patients with fulminant hepatic failure or patients with severe liver disease unrespon-

sive to chelation treatment should be treated with liver transplantation (II).

(16) Treatment for WD should be continued during pregnancy, but dosage reduction is advisable for D-penicillamine and trientine (III).

(17) Treatment is lifelong and should not be discontinued, unless a liver transplantation has been performed (II).

Treatment Targets and Monitoring of Treatment.

The goal of treatment monitoring is to confirm clinical and biochemical improvement, ensure compliance with therapy, and identify adverse side effects in a timely fashion. The frequency of monitoring of patients may vary for patients, but at a minimum should be performed twice a year. More frequent monitoring is needed for patients during the initial phase of treatment, for those experiencing worsening of symptoms or side effects of medications, and in individuals suspected of noncompliance with therapy. Physical examinations should look for evidence of liver disease and neurologic symptoms. Repeat examination for Kayser-Fleischer rings should be performed if there is a question of patient compliance as their appearance or reappearance in a patient in whom they were absent may portend the onset of symptomatic disease. For patients on penicillamine, cutaneous changes should be sought on physical examination. A careful history should also include questioning for psychiatric symptoms, especially depression.

Laboratory testing should include liver biochemistries including tests of hepatic synthetic function and indices of copper metabolism (serum copper and ceruloplasmin); the estimated serum nonceruloplasmin-bound copper may provide the best guide to treatment efficacy. Twenty-four-hour urinary copper excretion while on medication reflects overall exchangeable copper and is helpful for monitoring compliance. For patients taking D-penicillamine or trientine this should run 200 to 500 μg (3-8 μmoles) per day, and for patients on zinc it should be no more than 75 μg (1.2 μmoles) per day. Compliance in patients taking zinc can also be checked by measuring serum zinc or 24-hour urinary zinc excretion. The total blood count and differential should be monitored in all patients on chelators, and a urinalysis should be performed regularly to ensure safety.

Long-term outcome is dependent on adherence to lifelong treatment. Patients with WD who commence treatment before onset of symptomatic hepatic or neurologic disease have an excellent long-term prognosis and rarely develop symptoms. Appearance of hepatic or neurologic disease in these patients demands investigation of adequate adherence to therapy. Symptomatic patients may expect to stabilize or improve on treatment. A minority of

patients with neurologic disease experience worsening with initiation of therapy: some stabilize but some worsen despite treatment. The prognosis for patients with liver disease who adhere to effective treatment is excellent, even if cirrhosis was present at the time of diagnosis.

Recommendations: (18) For routine monitoring, serum copper and ceruloplasmin, liver biochemistries and international normalized ratio, and physical examination should be performed regularly (III).

(19) Twenty-four-hour urinary excretion of copper while on medication should be measured yearly, or more frequently if there are issues of compliance or if dosage of medications is adjusted. The serum nonceruloplasmin-bound copper may be estimated in these situations (III).

(20) Patients receiving chelators require a complete blood count with differential and urinalysis regularly no matter how long they have been on treatment (III).

Acknowledgment: The authors extend their thanks to their mentors, Dr. Irmin Sternlieb and the late Dr. Andrew Sass-Kortsak, their colleagues and patients for their many contributions.

References

- Gross PA, Barrett TL, Dellinger EP, Krause PJ, Martone WJ, McGowan JE, Jr., et al. Purpose of quality standards for infectious diseases. Infectious Diseases Society of America. Clin Infect Dis 1994;18:421.
- Wilson SAK. Progressive lenticular degeneration: a familial nervous disease associated with cirrhosis of the liver. Brain 1912;34:295-507.
- Fleischer B. Ueber einer der "Pseudosclerose" nahestehende bisher unbekannte Krankheit (gekennzeichnet durch Tremor, psychische Störungen, braeunliche Pigmentierung bestimmter Gewebe, insbesondere Such der Hornhautperipherie, Lebercirrhose). Deutsch Z Nerven Heilk 1912;44:179-201.
- Bearn AG. A genetical analysis of thirty families with Wilson's disease (hepatolenticular degeneration). Ann Hum Genet 1960;24:33-43.
- Bull PC, Thomas GR, Rommens JM, Forbes JR, Cox DW. The Wilson disease gene is a putative copper transporting P-type ATPase similar to the Menkes gene. Nat Genet 1993;5:327-337.
- Tanzi RE, Petrukhin K, Chernov I, Pellequer JL, Wasco W, Ross B, et al. The Wilson disease gene is a copper transporting ATPase with homology to the Menkes disease gene. Nat Genet 1993;5:344-350.
- Petrukhin K, Fischer SG, Pirastu M, Tanzi RE, Chernov I, Devoto M, et al. Mapping, cloning and genetic characterization of the region containing the Wilson disease gene. Nat Genet 1993;5:338-343.
- Yamaguchi Y, Heiny ME, Gitlin JD. Isolation and characterization of a human liver cDNA as a candidate gene for Wilson disease. Biochem Biophys Res Commun 1993;197:271-277.
- Holtzman NA, Gaumnitz BM. Studies on the rate of release and turnover of ceruloplasmin and apoceruloplasmin in rat plasma. J Biol Chem 1970;245:2354-2358.
- Frydman M. Genetic aspects of Wilson's disease. J Gastroenterol Hepatol 1990;5:483-490.
- Cumings JN. The effect of BAL in hepatolenticular degeneration. Brain 1951;74:10-22.
- Denny-Brown D, Porter H. The effect of BAL (2,3 dimercaptopropanol) on hepatolenticular degeneration (Wilson's disease). N Engl J Med 1951;245:917-925.
- Walshe JM. Wilson's disease. New oral therapy. Lancet 1956;i:25-26.
- Scheinberg IH, Gitlin D. Deficiency of ceruloplasmin in patients with hepatolenticular degeneration (Wilson's disease). Science 1952;116:484-485.

15. Sternlieb I. Perspectives on Wilson's disease. *HEPATOLOGY* 1990;12:1234-1239.
16. Steindl P, Ferenci P, Dienes HP, Grimm G, Pabinger I, Madl C, et al. Wilson's disease in patients presenting with liver disease: a diagnostic challenge. *Gastroenterology* 1997;113:212-218.
17. Walshe JM. The liver in Wilson's disease. In: Schiff L, Schiff ER, editors. *Diseases of the Liver*. 6th ed. Philadelphia: Lippincott, 1987:1037-1050.
18. Saito T. Presenting symptoms and natural history of Wilson disease. *Eur J Pediatr* 1987;146:261-265.
19. Scott J, Gollan JL, Samourian S, Sherlock S. Wilson's disease, presenting as chronic active hepatitis. *Gastroenterology* 1978;74:645-651.
20. Schilsky ML, Scheinberg IH, Sternlieb I. Prognosis of Wilsonian chronic active hepatitis. *Gastroenterology* 1991;100:762-767.
21. Milkiewicz P, Saksena S, Hubscher SG, Elias E. Wilson's disease with superimposed autoimmune features: report of two cases and review. *J Gastroenterol Hepatol* 2000;15:570-574.
22. Azizi E, Eshel G, Aladjem M. Hypercalciuria and nephrolithiasis as a presenting sign in Wilson disease. *Eur J Pediatr* 1989;148:548-549.
23. Nakada SY, Brown MR, Rabinowitz R. Wilson's disease presenting as symptomatic urolithiasis: a case report and review of the literature. *J Urol* 1994;152:978-979.
24. Chu CC, Huang CC, Chu NS. Recurrent hypokalemic muscle weakness as an initial manifestation of Wilson's disease. *Nephron* 1996;73:477-479.
25. Golding DN, Walshe JM. Arthropathy of Wilson's disease. Study of clinical and radiological features in 32 patients. *Ann Rheum Dis* 1977;36:99-111.
26. Factor SM, Cho S, Sternlieb I, Scheinberg IH, Goldfischer S. The cardiomyopathy of Wilson's disease. Myocardial alterations in nine cases. *Virchows Arch [Pathol Anat]* 1982;397:301-311.
27. Kuan P. Cardiac Wilson's disease. *Chest* 1987;91:579-583.
28. Hlubocka Z, Maracek Z, Linhart A, Kejrova E, Pospisilova L, Martasek P, et al. Cardiac involvement in Wilson disease. *J Inherit Metab Dis* 2002;25:269-277.
29. Weizman Z, Picard E, Barki Y, Moses S. Wilson's disease associated with pancreatitis. *J Pediatr Gastroenterol Nutr* 1988;7:931-933.
30. Carpenter TO, Carnes DL, Jr., Anast CS. Hypoparathyroidism in Wilson's disease. *N Engl J Med* 1983;309:873-877.
31. Klee JG. Undiagnosed Wilson's disease as cause of unexplained miscarriage. *Lancet* 1979;2:423.
32. Kaushansky A, Frydman M, Kaufman H, Homburg R. Endocrine studies of the ovulatory disturbances in Wilson's disease (hepatolenticular degeneration). *Fertil Steril* 1987;47:270-273.
33. Tarnacka B, Rodo M, Cichy S, Czlonkowska A. Procreation ability in Wilson's disease. *Acta Neurol Scand* 2000;101:395-398.
34. Walshe JM. Pregnancy in Wilson's disease. *Q J Med* 1977;46:73-83.
35. Wilson DC, Phillips MJ, Cox DW, Roberts EA. Severe hepatic Wilson's disease in preschool-aged children. *J Pediatr* 2000;137:719-722.
36. Kalach N, Seidman EG, Morin C, Rasquin-Weber A, O'Regan S, Laberge JM, et al. Acute liver failure from Wilson's disease in a five year-old child. *Can J Gastroenterol* 1993;7:610-612.
37. Gow PJ, Smallwood RA, Angus PW, Smith AL, Wall AJ, Sewell RB. Diagnosis of Wilson's disease: an experience over three decades. *Gut* 2000;46:415-419.
38. Danks DM, Metz G, Sewell R, Prewett EJ. Wilson's disease in adults with cirrhosis but no neurological abnormalities. *Br Med J* 1990;301:331-332.
39. Fleming CR, Dickson ER, Wahner HW, Hollenhorst RW, McCall JT. Pigmented corneal rings in non-Wilsonian liver disease. *Ann Intern Med* 1977;86:285-288.
40. Frommer D, Morris J, Sherlock S, Abrams J, Newman S. Kayser-Fleischer-like rings in patients without Wilson's disease. *Gastroenterology* 1977;72:1331-1335.
41. Tauber J, Steinert RF. Pseudo-Kayser-Fleischer ring of the cornea associated with non-Wilsonian liver disease. A case report and literature review. *Cornea* 1993;12:74-77.
42. Dunn LL, Annable WL, Kliegman RM. Pigmented corneal rings in neonates with liver disease. *J Pediatr* 1987;110:771-776.
43. LaRusso NF, Summerskill WH, McCall JT. Abnormalities of chemical tests for copper metabolism in chronic active liver disease: differentiation from Wilson's disease. *Gastroenterology* 1976;70:653-655.
44. Stremmel W, Meyerrose KW, Niederau C, Heffer H, Kreuzpaintner G, Strohmeyer G. Wilson disease: clinical presentation, treatment, and survival. *Ann Intern Med* 1991;115:720-726.
45. Emre S, Atillasoy EO, Ozdemir S, Schilsky M, Rathna Varma CV, Thung SN, et al. Orthotopic liver transplantation for Wilson's disease: a single-center experience. *Transplantation* 2001;72:1232-1236.
46. Sanchez-Albisua I, Garde T, Hierro L, Camarena C, Frauca E, de la Vega A, et al. A high index of suspicion: the key to an early diagnosis of Wilson's disease in childhood. *J Pediatr Gastroenterol Nutr* 1999;28:186-190.
47. Martins da Costa C, Baldwin D, Portmann B, Lolin Y, Mowat AP, Mieli-Vergani G. Value of urinary copper excretion after penicillamine challenge in the diagnosis of Wilson's disease. *HEPATOLOGY* 1992;15:609-615.
48. Giacchino R, Marazzi MG, Barabino A, Fasce L, Ciravegna B, Famularo L, et al. Syndromic variability of Wilson's disease in children. Clinical study of 44 cases. *Ital J Gastroenterol Hepatol* 1997;29:155-161.
49. Demirkiran M, Jankovic J, Lewis RA, Cox DW. Neurologic presentation of Wilson disease without Kayser-Fleischer rings. *Neurology* 1996;46:1040-1043.
50. Cairns JE, Williams HP, Walshe JM. "Sunflower cataract" in Wilson's disease. *Br Med J* 1969;3:95-96.
51. Schilsky ML, Scheinberg IH, Sternlieb I. Liver transplantation for Wilson's disease: indications and outcome. *HEPATOLOGY* 1994;19:583-587.
52. Esmali B, Burnstine MA, Martonyi CL, Sugar A, Johnson V, Brewer GJ. Regression of Kayser-Fleischer rings during oral zinc therapy: correlation with systemic manifestations of Wilson's disease. *Cornea* 1996;15:582-588.
53. Frieden E, Hsieh HS. Ceruloplasmin: the copper transport protein with essential oxidase activity. *Adv Enzymol* 1976;44:187-236.
54. Morell AG, Windsor J, Sternlieb I, Scheinberg IH. Measurement of the concentration of ceruloplasmin by determination of its oxidase activity. In: Sunderman SW, Sunderman SW, Jr., editors. *Laboratory Diagnosis of Liver Diseases*. St. Louis: Warren H. Green, 1968:193-195.
55. Schosinsky KH, Lehmann HP, Beeler MS. Measurement of ceruloplasmin from its oxidase activity in serum by use of *o*-dianisidine dihydrochloride. *Clin Chem* 1974;20:1556-1563.
56. Rosenberg EB, Strickland GT, Feng YS, Blackwell RQ. Comparison of immunologic and enzymatic methods for ceruloplasmin quantitation in Wilson's disease. *Taiwan I Hsueh Hui Tsa Chih* 1971;70:49-53.
57. Endo F, Taketa K, Nakamura K, Awata H, Tanoue A, Eda Y, et al. Measurement of blood holoceruloplasmin by EIA using a mouse monoclonal antibody directed to holoceruloplasmin. Implication for mass screening of Wilson disease. *J Inherit Metab Dis* 1994;17:616-620.
58. Hiymuta S, Shimizu K, Aoki T. Early diagnosis of Wilson's disease. *Lancet* 1993;342:56-57.
59. Yamaguchi Y, Aoki T, Arashima S, Ooura T, Takada G, Kitagawa T, et al. Mass screening for Wilson's disease: results and recommendations. *Pediatr Int* 1999;41:405-408.
60. Fuhrman MP, Herrmann V, Masidonski P, Eby C. Pancytopenia after removal of copper from total parenteral nutrition. *JPEN J Parenteral Enteral Nutr* 2001;24:361-366.
61. Menkes JH. Menkes disease and Wilson disease: two sides of the same copper coin. Part I: Menkes disease. *Europ J Paediatr Neurol* 1999;3:147-158.
62. Edwards CQ, Williams DM, Cartwright GE. Hereditary hypoceruloplasminemia. *Clin Genet* 1979;15:311-316.
63. Harris ZL, Klomp LW, Gitlin JD. Aceruloplasminemia: an inherited neurodegenerative disease with impairment of iron homeostasis. *Am J Clin Nutr* 1998;67(suppl):972S-977S.
64. Cauza E, Maier-Dobersberger T, Polli C, Kaserer K, Kramer L, Ferenci P. Screening for Wilson's disease in patients with liver diseases by serum ceruloplasmin. *J Hepatol* 1997;27:358-362.

65. Perman JA, Werlin SL, Grand RJ, Watkins JB. Laboratory measures of copper metabolism in the differentiation of chronic active hepatitis and Wilson disease in children. *J Pediatr* 1979;94:564-568.
66. Lau JY, Lai CL, Wu PC, Pan HY, Lin HJ, Todd D. Wilson's disease: 35 years' experience. *Q J Med* 1990;75:597-605.
67. Walshe JM. Wilson's disease presenting with features of hepatic dysfunction: a clinical analysis of eighty-seven patients. *Q J Med* 1989;70:253-263.
68. Scheinberg IH, Sternlieb I. Wilson's disease. Philadelphia: Saunders, 1984.
69. Danks DM. Disorders of copper transport. In: Scriver CR, Beaudet AL, Sly WS, Valle D, eds. *The Metabolic Basis of Inherited Disease*. New York: McGraw-Hill, 1995:4125-4158.
70. Roberts EA, Cox DW. Wilson disease. *Baillieres Clin Gastroenterol* 1998;12:237-256.
71. Gaffney D, Fell GS, O'Reilly DS. ACP Best Practice No 163. Wilson's disease: acute and presymptomatic laboratory diagnosis and monitoring. *J Clin Pathol* 2000;53:807-812.
72. Tu JB, Blackwell RQ. Studies on levels of penicillamine-induced cupriuresis in heterozygotes of Wilson's disease. *Metabolism* 1967;16:507-513.
73. Gross JB, Jr., Ludwig J, Wiesner RH, McCall JT, LaRusso NF. Abnormalities in tests of copper metabolism in primary sclerosing cholangitis. *Gastroenterology* 1985;89:272-278.
74. Garcia-Villarreal L, Daniels S, Shaw SH, Cotton D, Galvin M, Geskes J, et al. High prevalence of the very rare Wilson disease gene mutation Leu708Pro in the island of Gran Canaria (Canary Islands, Spain): a genetic and clinical study. *HEPATOLOGY* 2000;32:1329-1336.
75. Frommer DJ. Urinary copper excretion and hepatic copper concentrations in liver disease. *Digestion* 1981;21:169-178.
76. Song YM, Chen MD. A single determination of liver copper concentration may misdiagnose Wilson's disease. *Clin Biochem* 2000;33:589-590.
77. Lyon TD, Fell GS, Gaffney D, McGaw BA, Russell RI, Park RH, et al. Use of a stable copper isotope (^{65}Cu) in the differential diagnosis of Wilson's disease. *Clin Sci (Colch)* 1995;88:727-732.
78. Alt ER, Sternlieb I, Goldfischer S. The cytopathology of metal overload. *Int Rev Exp Pathol* 1990;31:165-188.
79. Ludwig J, Moyer TP, Rakela J. The liver biopsy diagnosis of Wilson's disease. *Methods in pathology*. *Am J Clin Pathol* 1994;102:443-446.
80. Stromeyer FW, Ishak KG. Histology of the liver in Wilson's disease: a study of 34 cases. *Am J Clin Pathol* 1980;73:12-24.
81. Strand S, Hofmann WJ, Grambihler A, Hug H, Volkmann M, Otto G, et al. Hepatic failure and liver cell damage in acute Wilson's disease involve CD95 (APO-1/Fas) mediated apoptosis. *Nat Med* 1998;4:588-593.
82. Goldfischer S, Sternlieb I. Changes in the distribution of hepatic copper in relation to the progression of Wilson's disease (hepatolenticular degeneration). *Am J Pathol* 1968;53:883-901.
83. Geller SA, Petrovic LM, Batts KB, Ferrell LM, Cohen C, Lewin K, et al. Histopathology of end-stage Wilson disease [Abstr]. *Mod Pathol* 2000;13:184A.
84. Sternlieb I. Mitochondrial and fatty changes in hepatocytes of patients with Wilson's disease. *Gastroenterology* 1968;55:354-367.
85. Feldmann G, Groussard O, Fauvert R. L'ultrastructure hépatique au cours de la maladie de Wilson [Hepatic ultrastructure in Wilson's disease]. *Biol Gastroenterol* 1969;2:137-160.
86. Sternlieb I. Fraternal concordance of types of abnormal hepatocellular mitochondria in Wilson's disease. *HEPATOLOGY* 1992;16:728-732.
87. Phillips MJ, Poucell S, Patterson J, Valencia P. *The Liver. An Atlas and Text of Ultrastructural Pathology*. New York: Raven Press, 1987.
88. Sternlieb I, Feldmann G. Effects of anticopper therapy on hepatocellular mitochondria in patients with Wilson's disease: an ultrastructural and stereological study. *Gastroenterology* 1976;71:457-461.
89. Guan R, Oon CJ, Wong PK, Foong WC, Wee A. Primary hepatocellular carcinoma associated with Wilson's disease in a young woman. *Postgrad Med J* 1985;61:357-359.
90. Polio J, Enriquez RE, Chow A, Wood WM, Atterbury CE. Hepatocellular carcinoma in Wilson's disease. Case report and review of the literature. *J Clin Gastroenterol* 1989;11:220-224.
91. Cheng WS, Govindarajan S, Redeker AG. Hepatocellular carcinoma in a case of Wilson's disease. *Liver* 1992;12:42-45.
92. van Wassenae-van Hall HN, van den Heuvel AG, Algra A, Hoogenraad TU, Mali WP. Wilson disease: findings at MR imaging and CT of the brain with clinical correlation. *Radiology* 1996;198:531-536.
93. Aisen AM, Martel W, Gabrielsen TO, Glazer GM, Brewer G, Young AB, et al. Wilson disease of the brain: MR imaging. *Radiology* 1985;157:137-141.
94. Brewer GJ, Dick RD, Johnson V, Wang Y, Yuzbasiyan-Gurkan V, Kluin K, et al. Treatment of Wilson's disease with ammonium tetrathiomolybdate. I. Initial therapy in 17 neurologically affected patients. *Arch Neurol* 1994;51:545-554.
95. Brewer GJ, Dick RD, Johnson VD, Brunberg JA, Kluin KJ, Fink JK. Treatment of Wilson's disease with zinc: XV long-term follow-up studies. *J Lab Clin Med* 1998;132:264-278.
96. Thomas GR, Roberts EA, Walshe JM, Cox DW. Haplotypes and mutations in Wilson disease. *Am J Hum Genet* 1995;56:1315-1319.
97. Maier-Dobersberger T, Mannhalter C, Rack S, Granditsch G, Kaserer K, Korninger L, et al. Diagnosis of Wilson's disease in an asymptomatic sibling by DNA linkage analysis. *Gastroenterology* 1995;109:2015-2018.
98. Vidaud D, Assouline B, Lecoz P, Cadranet JF, Chappuis P. Misdiagnosis revealed by genetic linkage analysis in a family with Wilson disease. *Neurology* 1996;46:1485-1486.
99. Shah AB, Chernov I, Zhang HT, Ross BM, Das K, Lutsenko S, et al. Identification and analysis of mutations in the Wilson disease gene (ATP7B): population frequencies, genotype-phenotype correlation, and functional analyses. *Am J Hum Genet* 1997;61:317-328.
100. Cosu P, Pirastu M, Nucaro A, Figus A, Balestrieri A, Borrone C, et al. Prenatal diagnosis of Wilson's disease by analysis of DNA polymorphism. *N Engl J Med* 1992;327:57.
101. Loudianos G, Figus AL, Loi A, Angius A, Dessi V, Deiana M, et al. Improvement of prenatal diagnosis of Wilson disease using microsatellite markers. *Prenat Diagn* 1994;14:999-1002.
102. Loudianos G, Dessi V, Lovicu M, Angius A, Figus A, Lilliu F, et al. Molecular characterization of Wilson disease in the Sardinian population—evidence of a founder effect. *Hum Mutat* 1999;14:294-303.
103. Thomas GR, Jensson O, Gudmundsson G, Thorsteinsson L, Cox DW. Wilson disease in Iceland: a clinical and genetic study. *Am J Hum Genet* 1995;56:1140-1146.
104. Kim EK, Yoo OJ, Song KY, Yoo HW, Choi SY, Cho SW, et al. Identification of three novel mutations and a high frequency of the Arg778Leu mutation in Korean patients with Wilson disease. *Hum Mutat* 1998;11:275-278.
105. Nanji MS, Nguyen VT, Kawasoe JH, Inui K, Endo F, Nakajima T, et al. Haplotype and mutation analysis in Japanese patients with Wilson disease. *Am J Hum Genet* 1997;60:1423-1429.
106. Caca K, Ferenci P, Kuhn HJ, Polli C, Willgerodt H, Kunath B, et al. High prevalence of the H1069Q mutation in East German patients with Wilson disease: rapid detection of mutations by limited sequencing and phenotype-genotype analysis. *J Hepatol* 2001;35:575-581.
107. Firneisz G, Lakatos PL, Szalay F, Polli C, Glant TT, Ferenci P. Common mutations of ATP7B in Wilson disease patients from Hungary. *Am J Med Genet* 2002;108:23-28.
108. Thomas GR, Forbes JR, Roberts EA, Walshe JM, Cox DW. The Wilson disease gene: spectrum of mutations and their consequences. *Nat Genet* 1995;9:210-217.
109. Palsson R, Jonasson JG, Kristjansson M, Bodvarsson A, Goldin RD, Cox DW, et al. Genotype-phenotype interactions in Wilson's disease: insight from an Icelandic mutation. *Eur J Gastroenterol Hepatol* 2001;13:433-436.
110. Roche-Sicot J, Benhamou JP. Acute intravascular hemolysis and acute liver failure associated as a first manifestation of Wilson's disease. *Ann Intern Med* 1977;86:301-303.
111. Hamlyn AN, Gollan JL, Douglas AP, Sherlock S. Fulminant Wilson's disease with haemolysis and renal failure: copper studies and assessment of dialysis regimens. *Br Med J* 1977;2:660-662.
112. McCullough AJ, Fleming CR, Thistle JL, Baldus WP, Ludwig J, McCall JT, et al. Diagnosis of Wilson's disease presenting as fulminant hepatic failure. *Gastroenterology* 1983;84:161-167.

113. Rector WG, Jr., Uchida T, Kanel GC, Redeker AG, Reynolds TB. Fulminant hepatic and renal failure complicating Wilson's disease. *Liver* 1984;4:341-347.
114. Enomoto K, Ishibashi H, Irie K, Okumura Y, Nomura H, Fukushima M, et al. Fulminant hepatic failure without evidence of cirrhosis in a case of Wilson's disease. *Jpn J Med* 1989;28:80-84.
115. Ferlan-Marolt V, Stepec S. Fulminant Wilsonian hepatitis unmasked by disease progression: report of a case and review of the literature. *Dig Dis Sci* 1999;44:1054-1058.
116. Shaver WA, Bhatt H, Combes B. Low serum alkaline phosphatase activity in Wilson's disease. *HEPATOLOGY* 1986;6:859-863.
117. Sallie R, Katsiyannakis L, Baldwin D, Davies S, O'Grady J, Mowat A, et al. Failure of simple biochemical indexes to reliably differentiate fulminant Wilson's disease from other causes of fulminant liver failure. *HEPATOLOGY* 1992;16:1206-1211.
118. Pitt P, Mowat A, Williams R, Hamilton E. Hepatic hypertrophic osteoarthropathy and liver transplantation. *Ann Rheum Dis* 1994;53:338-340.
119. Berman DH, Leventhal RI, Gavalier JS, Cadoff EM, Van Thiel DH. Clinical differentiation of fulminant Wilsonian hepatitis from other causes of hepatic failure. *Gastroenterology* 1991;100:1129-1134.
120. Nazer H, Ede RJ, Mowat AP, Williams R. Wilson's disease: clinical presentation and use of prognostic index. *Gut* 1986;27:1377-1381.
121. Zandman-Goddard G, Weiss P, Avidan B, Bar-Meir S, Shoenfeld Y. Acute varicella infection heralding Wilsonian crisis. *J Clin Gastroenterol* 1994;18:265-266.
122. Sallie R, Chiyende J, Tan KC, Bradley D, Portmann B, Williams R, et al. Fulminant hepatic failure resulting from coexistent Wilson's disease and hepatitis E. *Gut* 1994;35:849-853.
123. Lembowicz K, Kryczka W, Walewska-Zielecka B, Kubicka J. Wilson's disease coexisting with viral hepatitis type C: a case report with histological and ultrastructural studies of the liver. *Ultrastruct Pathol* 1999;23:39-44.
124. Sternlieb I, Scheinberg IH. Prevention of Wilson's disease in asymptomatic patients. *N Engl J Med* 1968;278:352-359.
125. Scheinberg IH, Sternlieb I, Schilsky M, Stockert RJ. Penicillamine may detoxify copper in Wilson's disease. *Lancet* 1987;ii:95.
126. Siegel RC. Collagen cross-linking effect of D-penicillamine on cross-linking in vitro. *J Biol Chem* 1977;252:254-259.
127. Lipsky PE, Ziff M. The effect of D-penicillamine on mitogen-induced human lymphocyte proliferation: synergistic inhibition by D-penicillamine and copper salts. *J Immunol* 1978;120:1006-1013.
128. Perrett D. The metabolism and pharmacology of D-penicillamine in man. *J Rheumatol Suppl* 1981;7:41-50.
129. Wiesner RH, Dickson ER, Carlson GL, McPhaul LW, Go VLW. The pharmacokinetics of D-penicillamine in man. *J Rheumatol Suppl* 1981;7:51-55.
130. Bergstrom RF, Kay DR, Harkcom TM, Wagner JG. Penicillamine kinetics in normal subjects. *Clin Pharmacol Ther* 1981;30:404-413.
131. Schuna A, Osman MA, Patel RB, Welling PB, Sundstrom WR. Influence of food on the bioavailability of penicillamine. *J Rheumatol* 1983;10:95-97.
132. Kukovetz WR, Beubler E, Kreuzig F, Moritz AJ, Nimberger G, Werner-Breitnecker L. Bioavailability and pharmacokinetics of D-penicillamine. *J Rheumatol* 1983;10:90-94.
133. Wei P, Sass-Kortsak A. Urinary excretion and renal clearance of D-penicillamine in humans and the dog. *Gastroenterology* 1970;58:288.
134. Falkmer S, Samuelson G, Sjolin S. Penicillamine-induced normalization of clinical signs, and liver morphology and histochemistry in a case of Wilson's disease. *Pediatrics* 1970;45:260-268.
135. Walshe JM. Copper chelation in patients with Wilson's disease. A comparison of penicillamine and triethylene tetramine dihydrochloride. *Q J Med* 1973;42:441-452.
136. Sass-Kortsak A. Wilson's disease. A treatable liver disease in children. *Pediatr Clin North Am* 1975;22:963-984.
137. Grand RJ, Vawter GF. Juvenile Wilson disease: histologic and functional studies during penicillamine therapy. *J Pediatr* 1975;87:1161-1170.
138. Sternlieb I. Copper and the liver. *Gastroenterology* 1980;78:1615-1628.
139. Czlonkowska A, Gajda J, Rodo M. Effects of long-term treatment in Wilson's disease with D-penicillamine and zinc sulphate. *J Neurol* 1996;243:269-273.
140. Walshe JM, Yealland M. Chelation treatment of neurological Wilson's disease. *Q J Med* 1993;86:197-204.
141. Brewer GJ, Terry CA, Aisen AM, Hill GM. Worsening of neurologic syndrome in patients with Wilson's disease with initial penicillamine therapy. *Arch Neurol* 1987;44:490-493.
142. Scheinberg IH, Jaffe ME, Sternlieb I. The use of trientine in preventing the effects of interrupting penicillamine therapy in Wilson's disease. *N Engl J Med* 1987;317:209-213.
143. Deutscher J, Kiess W, Scheers Schmidt G, Willgerodt H. Potential hepatotoxicity of penicillamine treatment in three patients with Wilson's disease. *J Pediatr Gastroenterol Nutr* 1999;29:628.
144. Shiono Y, Wakusawa S, Hayashi H, Takikawa T, Yano M, Okada T, et al. Iron accumulation in the liver of male patients with Wilson disease. *Am J Gastroenterol* 2001;96:3147-3151.
145. Walshe JM. Treatment of Wilson's disease with trientine (triethylene tetramine) dihydrochloride. *Lancet* 1982;1:643-647.
146. Walshe JM. The management of pregnancy in Wilson's disease treated with trientine. *Q J Med* 1986;58:81-87.
147. Kodama H, Murata Y, Iitsuka T, Abe T. Metabolism of administered triethylene tetramine dihydrochloride in humans. *Life Sci* 1997;61:899-907.
148. Sarkar B, Sass-Kortsak A, Clarke R, Laurie SH, Wei P. A comparative study of *in vitro* and *in vivo* interaction of D-penicillamine and triethylene-tetramine with copper. *Proc R Soc Med* 1977;70(Suppl 3):13-18.
149. Borthwick TR, Benson GD, Schugar HJ. Copper chelating agents. A comparison of cupruritic responses to various tetramines and D-penicillamine. *J Lab Clin Med* 1980;95:575-580.
150. Walshe JM. The management of Wilson's disease with triethylene tetramine 2HC1 (Trien 2HC1). *Prog Clin Biol Res* 1979;34:271-280.
151. Santos Silva EE, Sarles J, Buts JP, Sokal EM. Successful medical treatment of severely decompensated Wilson disease. *J Pediatr* 1996;128:285-287.
152. Saito H, Watanabe K, Sahara M, Mochizuki R, Edo K, Ohyama Y. Triethylene-tetramine (trien) therapy for Wilson's disease. *Tohoku J Exp Med* 1991;164:29-35.
153. Epstein O, Sherlock S. Triethylene tetramine dihydrochloride toxicity in primary biliary cirrhosis. *Gastroenterology* 1980;78:1442-1445.
154. Shiono Y, Hayashi H, Wakusawa S, Yano M. Ultrastructural identification of iron and copper accumulation in the liver of a male patient with Wilson disease. *Med Electron Microsc* 2001;34:54-60.
155. Hoogenraad TU, Van Hattum J, Van den Hamer CJ. Management of Wilson's disease with zinc sulphate. Experience in a series of 27 patients. *J Neurol Sci* 1987;77:137-146.
156. Hoogenraad TU, Koevoet R, de Ruyter Korver EG. Oral zinc sulphate as long-term treatment in Wilson's disease (hepatolenticular degeneration). *Eur Neurol* 1979;18:205-211.
157. Brewer GJ, Yuzbasiyan-Gurkan V, Young AB. Treatment of Wilson's disease. *Semin Neurol* 1987;7:209-220.
158. Brewer GJ, Hill GM, Prasad AS, Cossack ZT, Rabbani P. Oral zinc therapy for Wilson's disease. *Ann Intern Med* 1983;99:314-319.
159. Schilsky M, Blank RR, Czaja MJ, Scheinberg IH, Stockert RJ, Sternlieb I. Hepatocellular copper toxicity and its attenuation by zinc. *J Clin Invest* 1989;84:1562-1568.
160. Hill GM, Brewer GJ, Prasad AS, Hydrick CR, Hartmann DE. Treatment of Wilson's disease with zinc. I. Oral zinc therapy regimens. *HEPATOLOGY* 1987;7:522-528.
161. Cousins RJ. Absorption, transport and hepatic metabolism of copper and zinc: special reference to metallothionein and ceruloplasmin. *Physiol Rev* 1985;65:238-309.
162. Walshe JM, Munro NA. Zinc-induced deterioration in Wilson's disease aborted by treatment with penicillamine, dimercaprol, and a novel zero copper diet. *Arch Neurol* 1995;52:10-11.

163. Lang CJ, Rabas-Kolominsky P, Engelhardt A, Kobras G, Konig HJ. Fatal deterioration of Wilson's disease after institution of oral zinc therapy. *Arch Neurol* 1993;50:1007-1008.
164. Brewer GJ, Johnson V, Kaplan J. Treatment of Wilson's disease with zinc: XIV. Studies of the effect of zinc on lymphocyte function. *J Lab Clin Med* 1997;129:649-652.
165. Alexiou D, Hatzis T, Koutselinis A. [Maintenance treatment of Wilson's disease with oral zinc. Apropos of a child treated for 4 years]. *Arch Fr Pediatr* 1985;42:447-449.
166. Van Caillie-Bertrand M, Degenhart HJ, Visser HK, Sinaasappel M, Bouquet J. Oral zinc sulphate for Wilson's disease. *Arch Dis Child* 1985;60:656-659.
167. Milanino R, Deganello A, Marrella M, Michielutti F, Moretti U, Pasqualicchio M, et al. Oral zinc as initial therapy in Wilson's disease: two years of continuous treatment in a 10-year-old child. *Acta Paediatr* 1992;81:163-166.
168. Brewer GJ, Dick RD, Johnson VD, Fink JK, Kluin KJ, Daniels S. Treatment of Wilson's disease with zinc XVI: treatment during the pediatric years. *J Lab Clin Med* 2001;137:191-198.
169. Pecoud A, Dozel F, Schelling JL. The effect of foodstuffs on the absorption of zinc sulfate. *Clin Pharmacol Ther* 1975;17:469.
170. von Herbay A, de Groot H, Hegi U, Stremmel W, Strohmeyer G, Sies H. Low vitamin E content in plasma of patients with alcoholic liver disease, hemochromatosis and Wilson's disease. *J Hepatol* 1994;20:41-46.
171. Ogihara H, Ogihara T, Miki M, Yasuda H, Mino M. Plasma copper and antioxidant status in Wilson's disease. *Pediatr Res* 1995;37:219-226.
172. Sokol RJ, Twedt D, McKim JM, Jr., Devereaux MW, Karrer FM, Kam I, et al. Oxidant injury to hepatic mitochondria in patients with Wilson's disease and Bedlington terriers with copper toxicosis. *Gastroenterology* 1994;107:1788-1798.
173. Brewer GJ, Yuzbasiyan-Gurkan V, Dick R, Wang Y, Johnson V. Does a vegetarian diet control Wilson's disease? *J Am Coll Nutr* 1993;12:527-530.
174. Brewer GJ, Johnson V, Dick RD, Kluin KJ, Fink JK, Brunberg JA. Treatment of Wilson disease with ammonium tetrathiomolybdate. II. Initial therapy in 33 neurologically affected patients and follow-up with zinc therapy. *Arch Neurol* 1996;53:1017-1025.
175. Walshe JM. Diagnosis and treatment of presymptomatic Wilson's disease. *Lancet* 1988;2:435-437.
176. Brewer GJ, Yuzbasiyan-Gurkan V, Lee DY, Appelman H. Treatment of Wilson's disease with zinc. VI. Initial treatment studies. *J Lab Clin Med* 1989;114:633-638.
177. Walshe JM, Dixon AK. Dangers of non-compliance in Wilson's disease. *Lancet* 1986;1:845-847.
178. Sokol RJ, Francis PD, Gold SH, Ford DM, Lum GM, Ambruso DR. Orthotopic liver transplantation for acute fulminant Wilson disease. *J Pediatr* 1985;107:549-552.
179. Kiss JE, Berman D, Van Thiel D. Effective removal of copper by plasma exchange in fulminant Wilson's disease. *Transfusion* 1998;38:327-331.
180. Rakela J, Kurtz SB, McCarthy JT, Krom RA, Baldus WP, McGill DB, et al. Postdilution hemofiltration in the management of acute hepatic failure: a pilot study. *Mayo Clin Proc* 1988;63:113-118.
181. Rakela J, Kurtz SB, McCarthy JT, Ludwig J, Ascher NL, Bloomer JR, et al. Fulminant Wilson's disease treated with postdilution hemofiltration and orthotopic liver transplantation. *Gastroenterology* 1986;90:2004-2007.
182. Sarles J, Lefevre P, Picon G. Plasma exchange for fulminant Wilson disease. *Eur J Pediatr* 1992;151:310.
183. Kreyman B, Seige M, Schweigart U, Kopp KF, Classen M. Albumin dialysis: effective removal of copper in a patient with fulminant Wilson disease and successful bridging to liver transplantation: a new possibility for the elimination of protein-bound toxins. *J Hepatol* 1999;31:1080-1085.
184. Stange J, Mitzner SR, Risler T, Erley CM, Lauchart W, Goehl H, et al. Molecular adsorbent recycling system (MARS): clinical results of a new membrane-based blood purification system for bioartificial liver support. *Artif Organs* 1999;23:319-330.
185. Sen S, Felldin M, Steiner C, Larsson B, Gillett GT, Olausson M, et al. Albumin dialysis and Molecular Adsorbents Recirculating System (MARS) for acute Wilson's disease. *Liver Transpl* 2002;8:962-967.
186. Shimono N, Ishibashi H, Ikematsu H, Kudo J, Shirahama M, Inaba S, et al. Fulminant hepatic failure during perinatal period in a pregnant woman with Wilson's disease. *Gastroenterol Jpn* 1991;26:69-73.
187. Morimoto I, Ninomiya H, Komatsu K, Satho M. Pregnancy and penicillamine treatment in a patient with Wilson's disease. *Jpn J Med* 1986;25:59-62.
188. Dupont P, Irion O, Beguin F. Pregnancy in a patient with treated Wilson's disease: a case report. *Am J Obstet Gynecol* 1990;163:1527-1528.
189. Soong YK, Huang HY, Huang CC, Chu NS. Successful pregnancy after D-penicillamine therapy in a patient with Wilson's disease. *J Formos Med Assoc* 1991;90:693-696.
190. Devesa R, Alvarez A, de las Heras G, Ramon de Miguel J. Wilson's disease treated with trientine during pregnancy. *J Pediatr Gastroenterol Nutr* 1995;20:102-103.
191. Lao TT, Chin RK, Cockram CS, Leung NW. Pregnancy in a woman with Wilson's disease treated with zinc. *Asia Oceania J Obstet Gynaecol* 1988;14:167-169.
192. Brewer GJ, Johnson VD, Dick RD, Hedera P, Fink JK, Kluin KJ. Treatment of Wilson's disease with zinc. XVII: treatment during pregnancy. *HEPATOLOGY* 2000;31:364-370.
193. Endres W. D-penicillamine in pregnancy—to ban or not to ban? *Klin Wochenschr* 1981;59:535-537.
194. Biller J, Swiontoniowski M, Brazis PW. Successful pregnancy in Wilson's disease: a case report and review of the literature. *Eur Neurol* 1985;24:306-309.
195. Hartard C, Kunze K. Pregnancy in a patient with Wilson's disease treated with D-penicillamine and zinc sulfate. A case report and review of the literature. *Eur Neurol* 1994;34:337-340.
196. Nunns D, Hawthorne B, Goulding P, Maresh M. Wilson's disease in pregnancy. *Eur J Obstet Gynecol Reprod Biol* 1995;62:141-143.
197. Sternlieb I. Wilson's disease and pregnancy. *HEPATOLOGY* 2000;31:531-532.
198. Groth CG, Dubois RS, Corman J, Gustafsson A, Iwatsuki S, Rodgerson DO, et al. Metabolic effects of hepatic replacement in Wilson's disease. *Transplant Proc* 1973;5:829-833.
199. Eghtesad B, Nezakatgoo N, Geraci LC, Jabbour N, Irish WD, Marsh W, et al. Liver transplantation for Wilson's disease: a single-center experience. *Liver Transpl Surg* 1999;5:467-474.
200. Asonuma K, Inomata Y, Kasahara M, Uemoto S, Egawa H, Fujita S, et al. Living related liver transplantation from heterozygote genetic carriers to children with Wilson's disease. *Pediatr Transplant* 1999;3:201-205.
201. Schumacher G, Platz KP, Mueller AR, Neuhaus R, Steinmuller T, Bechstein WO, et al. Liver transplantation: treatment of choice for hepatic and neurological manifestation of Wilson's disease. *Clin Transplant* 1997;11:217-224.
202. Bax RT, Hassler A, Luck W, Hefter H, Krageloh-Mann I, Neuhaus P, et al. Cerebral manifestation of Wilson's disease successfully treated with liver transplantation. *Neurology* 1998;51:863-865.
203. Lui CC, Chen CL, Cheng YF, Lee TY. Recovery of neurological deficits in a case of Wilson's disease after liver transplantation. *Transplant Proc* 1998;30:3324-3325.
204. Stracciari A, Tempestini A, Borghi A, Guarino M. Effect of liver transplantation on neurological manifestations in Wilson disease. *Arch Neurol* 2000;57:384-386.
205. Wu JC, Huang CC, Jeng LB, Chu NS. Correlation of neurological manifestations and MR images in a patient with Wilson's disease after liver transplantation. *Acta Neurol Scand* 2000;102:135-139.
206. Guarino M, Stracciari A, D'Alessandro R, Pazzaglia P. No neurological improvement after liver transplantation for Wilson's disease. *Acta Neurol Scand* 1995;92:405-408.
207. Kassam N, Witt N, Kneteman N, Bain VG. Liver transplantation for neuropsychiatric Wilson disease. *Can J Gastroenterol* 1998;12:65-68.
208. Brewer GJ, Askari F. Transplant livers in Wilson's disease for hepatic, not neurologic, indications. *Liver Transpl* 2000;6:662-664.

Correction

The following acknowledgement was inadvertently omitted from "A Practice Guideline on Wilson Disease" by Eve A. Roberts and Michael L. Schilsky (HEPATOLOGY 2003;37:1475-1492):

This Guideline was commissioned and approved by the American Association for the Study of Liver Diseases (AASLD) and represents the position of the Association. It was produced in collaboration with the AASLD Practice Guidelines Committee in concert with additional external reviewers who supplied peer review of the guideline. Members of the AASLD Practice Guidelines Committee included: Henry C. Bodenheimer, Jr., M.D. (Chair), John M. Vierling, M.D., (Governing Board Liaison) David E. Bernstein, M.D., Gary L. Davis, M.D., James Everhart, M.D., Thomas W. Faust, M.D., Stuart C. Gordon, M.D., Donald M. Jensen, M.D., Jacob Korula, M.D., Thomas Shaw-Stiffel, M.D., Maureen Jonas, M.D., Michael Lucey, M.D., Timothy M. McCashland, M.D., Jan. M. Novak, M.D., Melissa Palmer, M.D., Rajender Reddy, M.D., Margaret C. Shurhart, M.D., and Brent A. Tetri, M.D. External review was provided by Ronald J. Sokol, M.D. and Anthony S. Tavill, M.D.